



# Effect of mitomycin-C on the variance in refractive outcomes after photorefractive keratectomy

Mary Ellen Sy, MD, Lijun Zhang, MD, Allen Yeroushalmi, MD, Derek Huang, MD, D. Rex Hamilton, MD, MS

**PURPOSE:** To compare the variance in manifest refraction spherical equivalent (MRSE) after photorefractive keratectomy (PRK) with mitomycin-C (MMC), PRK without MMC, and laser in situ keratomileusis (LASIK) for the treatment of myopic astigmatism.

**SETTING:** Jules Stein Eye Institute, University of California, Los Angeles, Los Angeles, California, USA.

**DESIGN:** Retrospective case series.

**METHODS:** Patients were classified into 3 groups of preoperative refraction-matched eyes as follows: PRK with MMC 0.02%, PRK without MMC, and LASIK. The preoperative and postoperative MRSE, preoperative corrected distance visual acuity, and postoperative uncorrected distance visual acuity (UDVA) were analyzed.

**RESULTS:** Each group comprised 30 eyes. Follow-up was at least 6 months in the LASIK group and 12 months in the 2 PRK groups. There were no statistically significant differences in the mean preoperative MRSE ( $P=.95$ ) or postoperative MRSE ( $P=.06$ ) between the 3 groups. The mean postoperative MRSE was  $-0.07$  diopter (D)  $\pm$  0.47 (SD),  $-0.14 \pm 0.26$  D, and  $0.02 \pm 0.25$  D in the PRK with MMC 0.02% group, PRK without MMC group, and LASIK group, respectively. The variance in the postoperative MRSE in the PRK with MMC 0.02% group was significantly higher than that in the PRK without MMC group ( $P=.002$ ) and in the LASIK group ( $P=.001$ ). There was no statistically significant difference in the mean postoperative UDVA between the 3 groups ( $P=.47$ ).

**CONCLUSIONS:** Refractive outcomes after PRK for myopia were more variable when MMC 0.02% was used. This should be weighed against the advantage of intraoperative MMC use in reducing haze after PRK.

**Financial Disclosures:** Dr. Hamilton has received honoraria for educational lectures from Alcon Laboratories. No other author has a financial or proprietary interest in any material or method mentioned.

*J Cataract Refract Surg 2014; 40:1980–1984 © 2014 ASCRS and ESCRS*

Laser in situ keratomileusis (LASIK) has become the most common method of surgical correction of refractive error because it causes less discomfort and provides a faster postoperative visual recovery than photorefractive keratectomy (PRK). Recently, there has been renewed interest in surface ablation techniques in an effort to avoid LASIK flap complications<sup>1,2</sup> and postoperative ectasia.<sup>3</sup> Photorefractive keratectomy has been used for corrections in patients with thinner corneas and those with corneal surface disease.

However, subepithelial haze formation can occur after PRK, resulting in decreased uncorrected (UDVA) and corrected (CDVA) distance visual acuities.<sup>4</sup> Mitomycin-C (MMC), an alkylating agent, has been used to modulate the healing response after PRK and reduce the occurrence of subepithelial haze.<sup>5–8</sup>

Recent research is continuing to elucidate the various long-term benefits and disadvantages of MMC use. The predictability of PRK with the use of MMC is controversial.<sup>6–7,9–11</sup> To date, we are unaware

of any study that evaluated the effect of MMC on the variance in refractive surgery outcomes. In this study, we analyzed the differences in the variance in the postoperative refractive error after PRK with MMC, PRK without MMC, and LASIK.

## PATIENTS AND METHODS

A retrospective chart review was performed to identify patients who had PRK or LASIK at the UCLA Laser Refractive Center, Jules Stein Eye Institute, David Geffen School of Medicine at UCLA, Los Angeles, California, USA, from January 2009 to May 2011. Preoperative data recorded included patient age, type of surgery, UDVA, CDVA, manifest refraction, and cycloplegic refraction. Eyes were placed into the following 3 groups: PRK with MMC, PRK without MMC, and LASIK. Eyes were chosen using 1-to-1 matching of the preoperative manifest refraction spherical equivalent (MRSE). The MRSE in the PRK without MMC group and LASIK group were matched within  $\pm 0.25$  diopter (D) to the MRSE in the consecutive PRK with MMC group. Exclusion criteria included previous refractive surgery and monovision target correction. The Institutional Review Board, University of California, Los Angeles, approved the study.

The same surgeon (D.R.H.) performed all surgeries using an Allegretto Wave 400 Hz Eye-Q excimer laser (Alcon Laboratories, Inc.) and a wavefront-optimized ablation profile. Programmed corrections were chosen for a postoperative MRSE target of plano after adjustments were made using nomograms (Datagraph Med) specific to the surgeon. Separate nomograms were used in the 3 study groups. Epithelial removal in PRK was performed using ethanol 20% applied to the cornea in a well for 30 seconds. The ethanol was absorbed with a sponge, and the eye was irrigated with a balanced salt solution to remove residual alcohol. Epithelial removal was performed over an 8.50 mm diameter using a micro-hoe. Ablation was performed and was immediately followed by application of a chilled balanced salt solution placed in a well on the cornea for 1 minute.

In eyes receiving MMC, a sponge soaked in MMC 0.02% was applied to the stromal bed for 30 seconds. The eye was then copiously irrigated with a balanced salt solution to remove the residual MMC. One drop of an antibiotic and steroid solution was given. A bandage contact lens

was placed and was left in place for 4 days to allow complete reepithelialization.

In the LASIK group, the flap was created with a One Use microkeratome with a 130 mm head (Moria, Inc.) or an Intra-lase FS 60 kHz femtosecond laser (Advanced Medical Optics, Inc.) using a 110 or 120 mm flap thickness setting and programmed flap diameters ranging between 8.90 mm and 9.10 mm. All eyes had an ablation with an optical zone diameter of 6.50 mm with a 1.25 mm blend zone, for a total treatment zone of 9.00 mm.

All patients were treated with topical steroid and antibiotic drops postoperatively. The PRK patients used moxifloxacin antibiotic drops (Vigamox) 4 times daily for 1 week and loteprednol steroid drops (Lotemax) 4 times daily for 4 weeks, then twice daily for 2 weeks, and then once daily for 2 weeks. Patients in the LASIK group used moxifloxacin antibiotic drops 4 times daily for 1 week and prednisolone acetate 1.0% 4 times daily for 1 week. In each eye, the manifest refraction was measured postoperative at 3, 6, and 12 months. The MRSE was recorded.

Statistical analysis was performed using Excel software (Microsoft Corp.) and SAS software (SAS Institute, Inc.). Analysis of variance and the Kruskal-Wallis test were used to compare the groups. The Student *t* test was used to compare visual acuity between groups, and the F test was used to compare the difference in variance between groups. A *P* value less than 0.05 was considered statistically significant.

## RESULTS

Table 1 shows the preoperative demographics, MRSE, and CDVA and the postoperative MRSE and UDVA in each of the 3 study groups. The PRK with MMC group, the PRK without MMC group, and the LASIK group comprised 30 eyes of 19 patients, 30 eyes of 20 patients, and 30 eyes of 24 patients, respectively. There was no statistically significant difference in age, preoperative MRSE, postoperative MRSE, preoperative CDVA, or postoperative UDVA between the 3 groups.

The mean postoperative UDVA in the PRK without MMC group and LASIK group was better than in the PRK with MMC group. More eyes in the PRK without MMC group and LASIK group than in the PRK with MMC group achieved a UDVA of 20/20 or better (Figure 1).

Although the preoperative mean MRSE and postoperative mean MRSE were not significantly different between the groups, the PRK with MMC group had a wider spread on the attempted correction versus the achieved correction graph than the other 2 groups (Figure 2). This wider spread in the postoperative MRSE in the PRK with MMC group was also seen when looking at the number of eyes within various ranges of postoperative MRSE (Figure 3).

Although the variance in the preoperative MRSE showed no significant difference ( $P=.996$ ,  $P=.997$ , and  $P=.999$ ), the variance in the postoperative MRSE in the PRK with MMC group (SD 0.47) was significantly higher than the variance in the PRK without MMC group (SD 0.26) ( $P=.002$ ). It was also

Submitted: December 22, 2013.

Final revision submitted: February 20, 2014.

Accepted: February 22, 2014.

From the American Eye Center (Sy), Makati, Manila, Philippines; the Refractive Center (Zhang), the 3rd Hospital of Dalian, Dalian, China; Weill Cornell Medical College (Yeroushalmi), New York, New York, and California Pacific Medical Center (Huang), San Francisco, and UCLA Laser Refractive Center (Hamilton), Jules Stein Eye Institute, David Geffen School of Medicine at University of California, Los Angeles, California, USA.

Corresponding author: D. Rex Hamilton, MD, MS, UCLA Laser Refractive Center, Jules Stein Eye Institute, 200 Stein Plaza, Room 1-340, Los Angeles, California 90095, USA. E-mail: [hamilton@jsei.ucla.edu](mailto:hamilton@jsei.ucla.edu).

**Table 1.** Preoperative and postoperative demographics, visual acuity, and manifest refraction by group.

Parameter	PRK With MMC	PRK Without MMC	LASIK	P Value*
Age (y)	33.37 ± 10.39	32.70 ± 10.28	33.03 ± 10.19	.97
Preop CDVA (logMAR)	0.043 ± 0.071	0.043 ± 0.068	0.033 ± 0.083	.42
MRSE (D)				
Preop				
Mean ± SD	-4.14 ± 1.42	-4.08 ± 1.42	-4.11 ± 1.42	.95
Range	-0.75, -7.00	-0.75, -6.88	-0.75, -7.00	
Postop				
Mean ± SD	-0.08 ± 0.50	-0.16 ± 0.33	0.01 ± 0.32	.06
Range	-1.25, 1.00	-0.75, 0.75	-0.50, 0.75	
Post UDVA (logMAR)	-0.00 ± 0.10	-0.02 ± 0.07	-0.03 ± 0.06	.47

CDVA = corrected distance visual acuity; LASIK = laser in situ keratomileusis; MMC = mitomycin-C; MRSE = manifest refraction spherical equivalent; PRK = photorefractive keratectomy; UDVA = uncorrected distance visual acuity  
 \*Kruskal-Wallis test

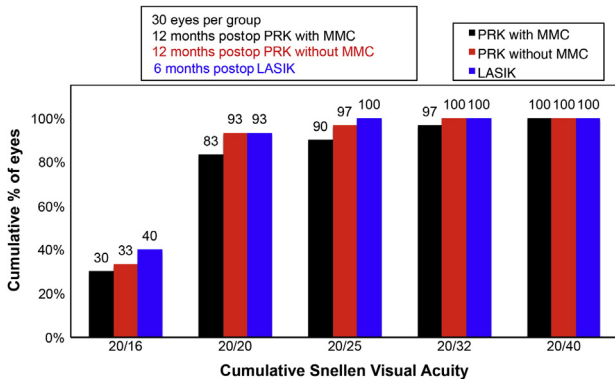
significantly higher than the variance in the LASIK group (SD 0.25) ( $P = .001$ ). However, there was no statistically significant difference between the variance in the PRK without MMC group (SD 0.26) and the variance in the LASIK group (SD 0.25) ( $P = .84$ ).

No intraoperative or postoperative complications occurred. No eye in either PRK group had visually significant subepithelial haze at any postoperative timepoint.

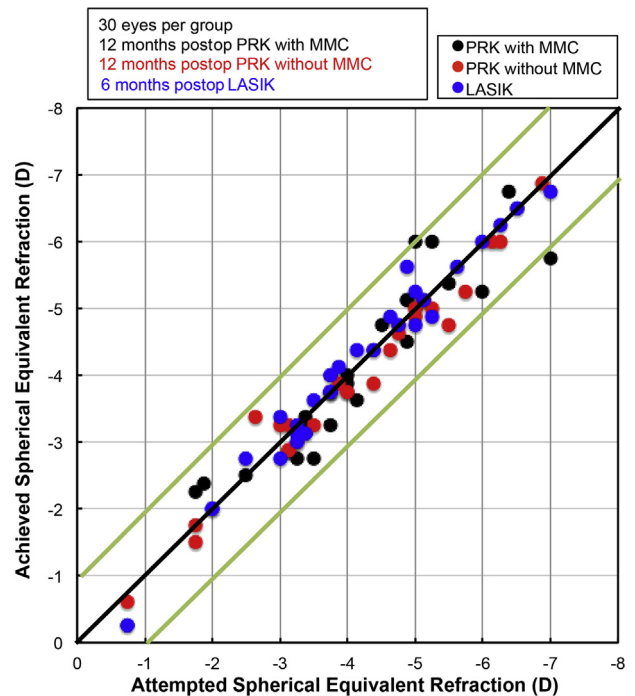
**DISCUSSION**

Optimizing predictability is a fundamental goal in refractive surgery. A few studies<sup>6,9-11</sup> report the predictability of outcomes after surface ablation with MMC. Carones et al.<sup>6</sup> evaluated the prophylactic use of MMC 0.02% after PRK in 30 eyes with medium to high myopia. They found smaller standard deviations with less variability at 6 months than after PRK alone. Predictability was slightly better after PRK without

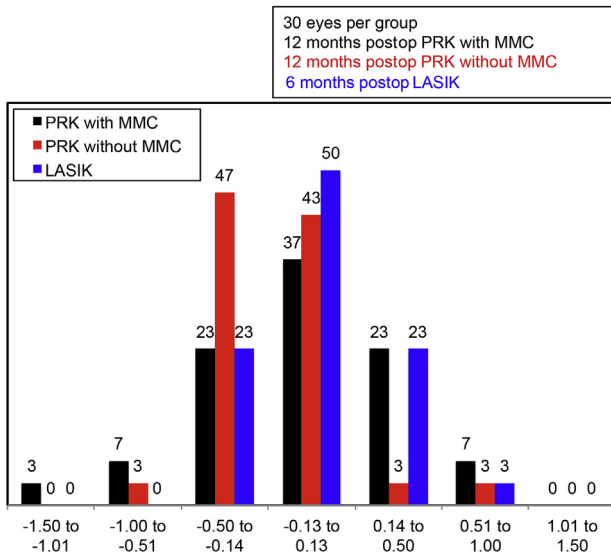
MMC than after PRK with MMC 0.02% in a study by Leccisotti.<sup>9</sup> Randleman et al.<sup>11</sup> found no significant difference in variability in the spherical equivalent refraction at 3 months between PRK with MMC eyes and LASIK eyes. However, Camellin<sup>10</sup> analyzed the results of laser-assisted subepithelial keratectomy (LASEK) with MMC 0.01% versus LASEK without MMC for low to high myopia. They found that the refractive outcome was less predictable with the use of MMC and hypothesized that this may have been



**Figure 1.** Postoperative UDVA cumulative Snellen visual acuity (LASIK = laser in situ keratomileusis; MMC = mitomycin-C; PRK = photorefractive keratectomy).



**Figure 2.** The attempted MRSE versus achieved refraction (LASIK = laser in situ keratomileusis; MMC = mitomycin-C; MRSE = manifest refraction spherical equivalent; PRK = photorefractive keratectomy).



**Figure 3.** Postoperative spherical equivalent refraction accuracy (LASIK = laser in situ keratomileusis; MMC = mitomycin-C; PRK = photorefractive keratectomy).

attributable to different drug penetrations or different epithelial responses from patient to patient. In a study by Chen et al.,<sup>12</sup> in vivo confocal microscopy showed that in the PRK with MMC group, the corneal basal epithelial cells returned to their preoperative morphology in 87.5% of cases after 1 month. However, in 52.4% of eyes in the PRK with MMC group, it took 6 months for the corneal apical surface epithelial cells to recover their squamous morphology. This suggests that the postoperative refraction result may not be stable even 6 months after surgery. A meta-analysis of the outcomes of surface ablation with and without MMC 0.02% showed no significant difference in the mean postoperative UDVA between the 2 groups.<sup>13</sup> However, these studies did not control for ablation depths.

In our study, the postoperative follow-up in the PRK with MMC group and the PRK without MMC group was at least 12 months, with most eyes having more than 12 months of follow-up. In addition, we matched the amount of ablation in each group to remove this variable from the effect on refractive outcomes because previous studies report a less predictable refractive endpoint with higher ablation depths in PRK and in LASIK.<sup>14</sup> We evaluated the effect of using MMC 0.02% after PRK on the variance in postoperative MRSE and found that MMC appears to significantly increase the variability relative to PRK without MMC and LASIK. We also found that eyes in the PRK without MMC and LASIK groups had better postoperative UDVA than eyes in the PRK with MMC group. This may simply indicate the need to adjust the nomogram in the PRK with MMC group

and is likely a finding independent of the higher variance found in that group.

Mitomycin-C has been shown to be a useful adjunct as a prophylactic agent against the occurrence of postoperative corneal haze after surface ablations.<sup>6,13</sup> Recent studies suggest that MMC reduces haze formation by inhibiting keratocyte proliferation and differentiation to haze-associated myofibroblasts. Mitomycin-C in doses up to 0.02% has not been associated with relevant epithelial corneal toxicity.<sup>15,16</sup> In our study, no significant haze developed after PRK with MMC or without MMC. The mean attempted refractive correction in all groups (MRSE  $-4.00$  D) was relatively low and likely below the typical threshold of haze formation reported in other studies.<sup>14</sup> In our study, the percentage of overcorrection of MRSE was higher in the PRK with MMC group (30%) than in the PRK without MMC group (6%). Similarly, the percentage of undercorrection of the MRSE ( $-0.50$  to  $-1.50$  D) was significantly higher in the PRK with MMC group (10%) than in the PRK without MMC group (3%) and LASIK group (0%). A possible explanation for this higher variability in refractive outcomes is that MMC has been shown to retard wound healing and decrease keratocyte density in treated corneas.<sup>9,15,16</sup> In addition, MMC alters corneal stromal wound healing by prolonging or reducing keratocyte apoptosis.<sup>17,18</sup> It is possible that the magnitude of this MMC effect differs from one patient to the next, leading to an unpredictable modulation in stromal and epithelial healing<sup>19</sup> that translates clinically into more variability in the postoperative refractive endpoint. Surgeons should take this clinical effect of MMC into consideration when deciding whether to use this alkylating agent when planning surface ablation treatments.

Our results must be evaluated considering the study limitations, which include a small sample size, a retrospective design, and the use of the same excimer laser (Allegretto 400 Hz Eye-Q). Because 1 excimer laser was used, results in this study should not be generalized to other types of excimer lasers.

This is the first study to report a variance in the postoperative MRSE after PRK with MMC, PRK without MMC, and LASIK after a follow-up of nearly 1 year and with matched attempted refractive corrections in each study group. Prospective studies with larger samples are recommended to confirm the results.

Alterations in MMC concentration and application time may decrease the variability in refractive outcomes without sacrificing its haze reduction advantages. Virasch et al.<sup>20</sup> found that reducing the application time of MMC 0.02% to 12 seconds maintained its efficacy in haze prevention. A study by Thornton et al.<sup>21</sup> found that low-dose MMC (0.002%)

and standard-dose MMC (0.020%) were equally effective in reducing haze formation in moderately myopic patients. A decrease in MMC concentration may be an option with the use of current flying-spot lasers, which induce less haze than older broad-beam lasers.<sup>22</sup> Further studies are needed to evaluate whether these modifications reduce the variability in postoperative refractive outcomes.

#### WHAT WAS KNOWN

- Mitomycin-C has been widely used to modulate the healing response and reduce the occurrence of subepithelial haze formation after PRK.
- The long-term benefits and disadvantages of MMC use and the predictability of PRK with the use of MMC are controversial.

#### WHAT THIS PAPER ADDS

- The refractive outcome after PRK for myopia was more variable when MMC 0.02% was used than when it was not used.
- The disadvantage of using intraoperative MMC should be weighed against its ability to reduce the occurrence of subepithelial haze after PRK.

#### REFERENCES

1. Moshirfar M, Gardiner JP, Schliesser JA, Espandar L, Feiz V, Mifflin MD, Chang JC. Laser in situ keratomileusis flap complications using mechanical microkeratome versus femtosecond laser: retrospective comparison. *J Cataract Refract Surg* 2010; 36:1925–1933
2. Clare G, Moore TCB, Grills C, Leccisotti A, Moore JE, Schallhorn S. Early flap displacement after LASIK. *Ophthalmology* 2011; 118:1760–1765
3. Klein SR, Epstein RJ, Randleman JB, Stulting RD. Corneal ectasia after laser in situ keratomileusis in patients without apparent preoperative risk factors. *Cornea* 2006; 25:388–403
4. Møller-Pedersen T, Cavanagh HD, Petroll WM, Jester JV. Stromal wound healing explains refractive instability and haze development after photorefractive keratectomy; a 1-year confocal microscopic study. *Ophthalmology* 2000; 107:1235–1245
5. Santiago MR, Netto MV, Wilson SE. Mitomycin C: biological effects and use in refractive surgery. *Cornea* 2012; 31:311–321
6. Carones F, Vigo L, Scandola E, Vacchini L. Evaluation of the prophylactic use of mitomycin-C to inhibit haze formation after photorefractive keratectomy. *J Cataract Refract Surg* 2002; 28:2088–2089
7. Gambato C, Ghirlando A, Moretto E, Busato F, Midena E. Mitomycin C modulation of corneal wound healing after photorefractive keratectomy in highly myopic eyes. *Ophthalmology* 2005; 112:208–218; discussion by RS Rubinfeld, 219
8. Wallau AD, Campos M. One-year outcomes of a bilateral randomized prospective clinical trial comparing PRK with mitomycin C and LASIK. *Br J Ophthalmol* 2009; 93:1634–1638. Available at: <http://www.ncbi.nlm.nih.gov/pmc/articles/PMC2777274/pdf/BJ1-93-12-1634.pdf>. Accessed June 27, 2014
9. Leccisotti A. Mitomycin C in photorefractive keratectomy; effect on epithelialization and predictability. *Cornea* 2008; 27:288–291
10. Camellin M. Laser epithelial keratomileusis with mitomycin C: indications and limits. *J Refract Surg* 2004; 20:S693–S698
11. Randleman JB, Loft ES, Banning CS, Lynn MJ, Stulting RD. Outcomes of wavefront-optimized surface ablation. *Ophthalmology* 2007; 114:983–988
12. Chen W-L, Chang H-W, Hu F-R. In vivo confocal microscopic evaluation of corneal wound healing after epi-LASIK. *Invest Ophthalmol Vis Sci* 2008; 49:2416–2423. Available at: <http://www.iovs.org/content/49/6/2416.full.pdf>. Accessed June 27, 2014
13. Chen S-H, Feng Y-F, Stojanovic A, Wang Q-M. Meta-analysis of clinical outcomes comparing surface ablation for correction of myopia with and without 0.02% mitomycin C. *J Refract Surg* 2011; 27:530–541
14. Lin N, Yee SB, Mitra S, Chuang AZ, Yee RW. Prediction of corneal haze using an ablation depth/corneal thickness ratio after laser epithelial keratomileusis. *J Refract Surg* 2004; 20:797–802
15. Thornton I, Puri A, Xu M, Krueger RR. Low-dose mitomycin C as a prophylaxis for corneal haze in myopic surface ablation. *Am J Ophthalmol* 2007; 144:673–681
16. Netto MV, Mohan RR, Sinha S, Sharma A, Gupta PC, Wilson SE. Effect of prophylactic and therapeutic mitomycin C on corneal apoptosis, cellular proliferation, haze, and long-term keratocyte density in rabbits. *J Refract Surg* 2006; 22:562–574
17. Lai Y-H, Wang H-Z, Lin C-P, Chang S-J. Mitomycin C alters corneal stromal wound healing and corneal haze in rabbits after argon-fluoride excimer laser photorefractive keratectomy. *J Ocul Pharmacol Ther* 2004; 20:129–138
18. Lee KS, Ko D-A, Kim E-S, Kim MJ, Tchah H, Kim JY. Bevacizumab and rapamycin can decrease corneal opacity and apoptotic keratocyte number following photorefractive keratectomy. *Invest Ophthalmol Vis Sci* 2012; 53:7645–7653. Available at: <http://www.iovs.org/content/53/12/7645.full.pdf>. Accessed June 27, 2014
19. Inatomi T, Nakamura T, Koizumi N, Sotozono C, Kinoshita S. Current concepts and challenges in ocular surface reconstruction using cultivated mucosal epithelial transplantation. *Cornea* 2005; 24(8 suppl):S32–S38
20. Virasch VV, Majmudar PA, Epstein RJ, Vaidya NS, Dennis RF. Reduced application time for prophylactic mitomycin C in photorefractive keratectomy. *Ophthalmology* 2010; 117:885–889
21. Thornton I, Xu M, Krueger RR. Comparison of standard (0.02%) and low dose (0.002%) mitomycin C in the prevention of corneal haze following surface ablation for myopia. *J Refract Surg* 2008; 24:S68–S76
22. Fiore T, Carones F, Brancato R. Broad beam vs. flying spot excimer laser: refractive and videokeratographic outcomes of two different ablation profiles after photorefractive keratectomy. *J Refract Surg* 2001; 17:534–541