

Medical and surgical management of the small pupil during cataract surgery



Saba Al-Hashimi, MD, Kendall Donaldson, MD, MS, Richard Davidson, MD, Deepinder Dhaliwal, MD, Mitchell Jackson, MD, Jeremy Z. Kieval, MD, Larry Patterson, MD, Karl Stonecipher, MD, David R. Hamilton, MD, for the ASCRS Refractive Cataract Surgery Subcommittee

As cataract surgery continues to evolve, the intraoperative small pupil continues to pose challenges to even the most experienced cataract surgeon. Several steps can be taken preoperatively to decrease the chance of intraoperative miosis. Even so, the problem of miosis during cataract surgery remains a relatively common occurrence. This paper discusses many steps, both preoperative and intraoperative, that can make surgery technically easier and

safer, thus maximizing the postoperative outcomes and patient satisfaction. Complications associated with small-pupil cataract surgery, risk factors for intraoperative miosis, the preoperative and intraoperative management of the small pupil during cataract surgery, and postoperative care are reviewed.

J Cataract Refract Surg 2018; 44:1032–1041 © 2018 ASCRS and ESCRS

An intraoperative small pupil can pose challenges to even the most experienced cataract surgeon. By limiting visualization, an inadequately dilated pupil can make safe and efficient cataract surgery more difficult. With a higher chance of iris damage, the patient might be left with increased postoperative inflammation and iris defects that can be cosmetically unacceptable or contribute to visual disturbances. Sufficient dilation and maintenance throughout the case help facilitate the creation of an appropriately sized capsulorhexis, the safe removal of lens material, and the successful insertion of the intraocular lens (IOL) into the capsular bag. Proper centration of IOLs and the orientation of toric IOLs are also more easily accomplished with a well-dilated pupil.

Several steps can be taken preoperatively to decrease the chance of intraoperative miosis during cataract surgery. Even so, the problem of miosis during cataract surgery remains a relatively common occurrence that every surgeon will experience. This is especially true with the increasing use of femtosecond laser–assisted cataract surgery. Several techniques and devices have been developed to help mitigate this challenge. Preparation begins long before surgery with the identification of patients at increased risk, medical pretreatment, and proper surgical preparation. Without

recognizing these critical elements, the surgeon is more likely to encounter challenges resulting from a small pupil and/or floppy iris that can lead to significant complications.

COMPLICATIONS ASSOCIATED WITH SMALL-PUPIL CATARACT SURGERY

Potential complications related to small pupils include, but are not limited to, capsule tear with or without vitreous loss, postoperative ocular hypertension, iris damage such as corectopia and transillumination defects, improper IOL placement, and retained lens fragments.^{1–3} Increased inflammation caused by iris manipulation can lead to a higher incidence of postoperative cystoid macular edema (CME).⁴ When recognized preoperatively, the surgeon should inform the patient that an increased risk for complications exists because of poor pupil dilation and/or the use of medications that increase the likelihood of intraoperative miosis and intraoperative floppy-iris syndrome (IFIS).

It is important to specifically mention that a loss of pigment (especially in light-colored eyes) can result in visual disturbances postoperatively. A small pupil increases the chance of inadvertently engaging the iris by the phacoemulsification tip, resulting in iris damage. In severe cases, in particular with lighter irides, the patient might perceive

Submitted: December 11, 2016 | Final revision submitted: February 23, 2018 | Accepted: February 28, 2018

From the Stein Eye Institute and Department of Ophthalmology (Al-Hashimi, Hamilton), David Geffen School of Medicine, University of California Los Angeles, Los Angeles, California, the Bascom Palmer Eye Institute (Donaldson), Miller School of Medicine, Plantation, Florida, the University of Colorado Eye Center (Davidson), University of Colorado School of Medicine, Denver, Colorado, the UPMC Eye Center (Dhaliwal), University of Pittsburgh School of Medicine, Pittsburgh, Pennsylvania, Jacksoneye (Jackson), Lake Villa, Illinois, Lexington Eye Associates (Kieval), Lexington, Massachusetts, Eye Centers of Tennessee (Patterson), Crossville, Tennessee, and the Department of Ophthalmology (Stonecipher), University of North Carolina, Chapel Hill, North Carolina, USA.

Corresponding author: Kendall Donaldson, MD, MS, Bascom Palmer Eye Institute, 8100 Southwest 10th Street, 3rd Floor, Plantation, Florida 33324, USA. Email: kdonaldson@med.miami.edu.

such iris defects as cosmetically disfiguring. Transillumination defects from pigment loss can occur simply from manipulation of the iris using iris hooks or other iris retraction devices. Mechanical manipulation of the iris to enlarge the pupil can also result in permanent changes to the shape or size of the pupil by damaging the iris sphincter.⁵ This is more common when using iris hooks than ring manipulators.⁶ Cosmetic iris defects can sometimes be repaired with a variety of suturing techniques, depending on their size and location. In addition, colored or cosmetic contact lenses can help alleviate patients' glare and photosensitivity symptoms.

A smaller pupil aperture carries with it an increased risk for anterior and posterior capsule tears and vitreous loss. Anterior capsule tears can occur because of the difficulty seeing the anterior capsule, even when dilating devices are used. The same holds true for posterior capsule tears and vitreous loss. Care should be taken during the lens fragmentation steps of phacoemulsification to avoid both these complications by adjusting parameters to allow maintenance of the phaco tip as close to the center of the eye as possible.^{1,2,7}

The presence of a small pupil can result in retained cortex or lens fragments even in an otherwise uneventful surgery.³ Modern phacoemulsification machines and femtosecond lasers help facilitate fragmentation of the crystalline lens into very small pieces, in particular when waffle-pattern fragmentation techniques are used. As a result, these pieces can become trapped behind the iris during routine phacoemulsification. This can lead to excessive postoperative inflammation. If an unusual amount of postoperative inflammation is noted, the surgeon should look carefully for a retained lens fragment. If a patient presents with unexpected persistent corneal edema, in particular involving the inferior cornea, one should look for a retained lens fragment in the inferior angle. Gonioscopy, ultrasound biomicroscopy, and anterior segment optical coherence tomography (OCT) can help facilitate confirmation.⁸

One-day postoperative intraocular pressure (IOP) spikes are also more common in the setting of a small pupil.⁵ This was shown by Bonnell et al.,³ who found that patients taking tamsulosin were 3.8 times more likely to have a 1-day postoperative IOP of 30 mm Hg or higher. The authors theorized that this might be related to an unstable iris during irrigation/aspiration (I/A) leading to incomplete evacuation of the ophthalmic viscosurgical device (OVD).

Cystoid macular edema can occur idiosyncratically with uneventful phacoemulsification surgery. When IFIS is encountered or if iris manipulation using surgical devices is performed, increased inflammation can result, increasing the risk for postoperative CME. The surgeon should be on the lookout for this condition and if vision unexpectedly decreases, should have a low threshold for obtaining macular OCT imaging and for increasing postoperative steroids and/or nonsteroidal eyedrops for prophylaxis or treatment of this vision-threatening condition.⁴

RISK FACTORS FOR INTRAOPERATIVE MIOSIS

Medical Conditions Causing Miosis

Pseudoexfoliation Syndrome Patients with pseudoexfoliation syndrome (PXF) are known to have a higher risk for complications during cataract surgery resulting from poor pupil dilation and compromised zonular integrity.⁹ There is atrophy of the iris sphincter and dilator muscles in eyes with PXF, especially at the pupil margin, as shown by peripupillary transillumination defects on slitlamp examination. This has been hypothesized to result from tissue hypoxia.¹⁰ Reduction of stromal elasticity by the accumulation of PXF material and impairment of iris smooth muscle cell function by PXF fiber formation can also contribute to poor pupillary dilation.¹⁰ Pseudoexfoliation has been recognized as the most common identifiable cause of glaucoma and is frequently associated with secondary open-angle glaucoma.^{6,11} Nordic countries are reported to have the highest prevalence rates, as high as 40.6% in those older than 80 years.¹²

Uveitis The development of cataracts in patients with uveitis is common because of chronic, sometimes severe, intraocular inflammation and the prolonged use of topical corticosteroid agents. In addition, iris atrophy and posterior synechiae are common uveitic sequelae, leading to poor or nondilating pupils. Patients with uveitis are also more susceptible to CME because of their predilection toward ocular inflammation. Unfortunately, mechanical dilation of the pupil is often requisite during the treatment of uveitic cataracts, leading to a further increase in the risk for postoperative CME. A recent study by Chu et al.¹³ found that the intraoperative pupil tends to remain small in nearly one third of uveitic patients and that uveitic patients are at increased risk for CME. Thus, in cases of uveitic cataracts cataract surgeons should consider pretreatment with topical and/or systemic corticosteroids or other steroid-sparing antiinflammatory agents as well as a prolonged postoperative course of topical corticosteroids.

Diabetes Compared with nondiabetic patients, the resting pupil in diabetic patients is smaller. In addition, the response to mydriatic agents is weaker. The loss of sympathetic tone due to diabetic neuropathy is thought to be responsible for this effect and for this reason the addition of sympathomimetic agents, such as topical phenylephrine preoperatively and intracameral preservative-free bisulfite-free phenylephrine or epinephrine, can produce adequate mydriasis comparable to that in healthy patients.^{14,15} In addition, constriction of the pupil during cataract surgery is more pronounced in eyes of diabetic patients.¹⁶

Previous Ocular Trauma Ocular trauma can often produce the combination of cataract and pupil irregularity, in particular in the face of penetrating trauma. Other effects of ocular trauma, including inflammation, hyphema, increased IOP, and zonular fiber disruption, can add additional complexities to the treatment of traumatic cataract in patients with poor pupil dilation. A careful slitlamp examination,

including maximum pupil dilation and gonioscopy, can assist the surgeon in creating an appropriate surgical plan for these potentially complex cases.

Mature Cataracts A mature or hypermature cataract can present in very elderly patients or in younger patients with a history of ocular trauma or uveitis. It is not uncommon for IFIS to develop in these cases as a result of preexisting iris dilator muscle atrophy, increased fluid flow related to prolonged phacoemulsification time, or both. Intraoperative pupil miosis can make the removal of a large, dense cataract more challenging. In a series of 212 patients with white cataract, 3.3% developed intraoperative pupillary miosis.¹⁷ When treating dense cataracts, the surgeon should consider the use of additional topical preoperative nonsteroidal, anticholinergic, and sympathomimetic agents and intracameral preservative-free bisulfite-free phenylephrine or epinephrine. In addition, the surgeon should have a low threshold for using mechanical pupil dilation in anticipation of prolonged phacoemulsification time and the resulting increased fluid flow.

Surgical Causes of Miosis

Femtosecond Laser Treatment Femtosecond laser-assisted cataract surgery can improve the consistency of outcomes¹⁸ but is known to cause pupillary miosis. In a study by Jun et al.,¹⁹ the mean pupil area decreased by 29.7% and this was correlated with the duration of laser pretreatment, laser capsulotomy–pupil margin distance, and patient age. Another study by Schultz et al.²⁰ identified laser creation of the anterior capsulotomy as the primary trigger for increased prostaglandin release, resulting in pupillary miosis. The use of intracameral sympathomimetic agents, such as preservative-free bisulfite-free phenylephrine and epinephrine, can be useful for dilation of miotic pupils resulting from femtosecond laser-assisted cataract surgery energy application.²¹ Should intraoperative manipulation of the pupil be required after femtosecond laser-created capsulotomy, care should be taken to viscodilate the pupil to improve visualization of the capsulorhexis and proper placement of the dilation device being used to avoid inadvertent manipulation of the anterior capsule and subsequent tear. Given the correlation between the proximity of the laser capsulorhexis to the pupil margin and the likelihood of pupillary miosis, the surgeon should consider reduction of energy levels for capsulotomy creation in eye with poor preoperative pupil dilation.

Previous Intraocular Surgery Any intraocular surgical intervention, whether straightforward or complicated, can challenge future interventions and traditional dilation techniques. Previous surgeries involving manipulation of the iris or surgeries complicated by a postoperative pressure spike (eg, pars plana vitrectomy with gas injection, corneal transplantation) can have permanent effects on the ability to pharmacologically dilate the pupil. Surgeons performing secondary intraocular surgeries (eg, IOL repositioning, IOL exchange, iris-fixation of IOL, scleral fixation of IOL) should be prepared for poor iris dilation. Donnenfeld

et al.^A showed that the scotopic pupil size, pupil constriction to a photopic stimulus, and pupil constriction velocity were reduced after for up to 60 days cataract surgery.

Duration of Surgery Prolonged surgical time is associated with a higher release of natural prostaglandins that stimulate inflammation, resulting in progressive intraoperative pupillary miosis. Kremer et al.²² analyzed aqueous samples and found that ocular trauma increased prostaglandin release, a phenomenon that can be inhibited by nonsteroidal antiinflammatory drugs (NSAIDs).

MEDICATIONS CAUSING MIOSIS

Systemic α -Adrenergic Blockers

Tamsulosin (Flomax) is the most commonly prescribed medication in male patients with benign prostatic hypertrophy (BPH). Its presence in the cataract population has been estimated to be as high as 3%.²³ It has been shown to contribute to IFIS and poor mydriasis.²³ Other medications in this category include terazosin (Hytrin), doxazosin (Cardura), and prazosin (Minipress). These agents block the α -1 adrenergic receptors of the iris dilator muscle as well as those found in the prostate.

Saw palmetto, an herb extract, has also been used in the treatment of BPH. Although the exact mechanism of action is unknown, studies have shown possible inhibition of α -1 adrenoreceptors similar to known α -1 adrenergic blockers and has been associated with IFIS and intraoperative miosis.^{24–26} The correlation with the duration of use of these agents and the incidence of pupillary miosis or IFIS is weak.²³ Therefore, even if a patient has a remote history of tamsulosin use with rapid discontinuation, the surgeon should go into the surgery prepared for IFIS.

Although these medications are primarily used for the treatment of BPH in men, they are also prescribed for the treatment of high blood pressure and urinary retention in women. Thus, a complete medical history, including identification of BPH and hypertension in men and hypertension and urinary retention in women, together with a thorough history of past and present medication use, are critical in the identification of patients with pharmacologically induced pupillary miosis and a subsequent risk for IFIS.

Topical Medications for Treatment of Glaucoma

In past years, a variety of miotic medications were used as therapy to lower IOP in patients with glaucoma. These medications have been associated with permanent pupillary miosis related to synechiae or poor dilation from hypertrophy of the pupillary sphincter muscle.²⁷ These drugs, either cholinergic-stimulating or parasympathomimetic agents such as pilocarpine and carbachol, were commonly used before the development of newer classes of medications that are better tolerated and require less frequent dosing. Other miotic therapies still available but rarely used are anticholinesterase-blocking drugs (demecarium, echothiopate, neostigmine, and physostigmine).

Figure 1 shows medications that cause miosis. Figure 2 shows additional conditions that cause miosis.

Alpha adrenergic antagonist drugs

Tamsulosin (Flomax)
 Doxazosin (Cardura)
 Terazosin (Hytrin)
 Prazosin (Minipress)
 Dutasteride/Tamsulosin (Jalyn)
 Alfuzosin (Uroxatral)
 Silodosin (Rapaflo)
 Fenasteride (Propecia)
 Tolterodine (Detrol)

Other drugs

Opioids (fentanyl, morphine, heroin, methadone)
 Nicotine
 Antipsychotics (risperdal, haloperido, thorazine, olanzapine, quetiapine)
 Cholinergics (acetylcholine)
 Imidazolines (clonidine, naphzoline, oxymetazoline, terahyrozoline)
 MAO Inhibitors (isocarboxazid)
 Chemotherapy drugs (camptothecin)
 Antiemetics (Ondansetron)
 Mirtazapine, a noradrenergic and specific serotonergic antidepressant
 Pilocarpine eyedrops and all other parasympathomimetics
 Organophosphates

Figure 1. Pharmacologic causes of miosis (MAO = monoamine oxidase).

PREOPERATIVE MANAGEMENT

A typical preoperative dilation regimen for routine cataract surgery consists of a short-acting and/or moderately long-acting anticholinergic agent such as tropicamide 1.0% and/or cyclopentolate 1.0%, together with a sympathomimetic agent, such as phenylephrine 2.5%, placed in the operative eye by repeated topical administration or by a pledget placed in the inferior fornix in the preoperative area before surgery. Phenylephrine 10.0% has not been shown to provide additional mydriasis compared with phenylephrine 2.5%, and the increased risk for cardiovascular side effects associated with the higher concentration warrants consideration in some cases.^{28,29}

Many researchers have studied the role of preoperative administration of topical NSAIDs to inhibit surgically induced miosis.³⁰ Prostaglandins are known to act on iris smooth muscle fibers, leading to pupil constriction.³¹

Other causes

Adie tonic pupil syndrome
 Argyll Robertson pupil
 Marcus Gunn pupil
 Parinaud syndrome
 Glaucoma
 Horner syndrome
 Hemorrhage into pons (intracranial hemorrhage)
 Hereditary disorders
 Cluster headaches with ptosis
 Iridocyclitis
 Fatal familial insomnia

Figure 2. Other causes of miosis.

Topical NSAIDs are potent cyclooxygenase inhibitors that effectively block the metabolism of arachidonic acid into prostaglandins, thus reducing their release and subsequent adverse effect on pupillary dilation. Flurbiprofen 0.03% was the first topical NSAID approved by the U.S. Food and Drug Administration (FDA) in 1986 for the prevention of intraoperative miosis. Early studies demonstrated that the preoperative use of flurbiprofen 0.03% significantly reduced intraoperative miosis with a 1.4 mm mean difference in postsurgical pupillary diameters compared to controls ($P < .003$).³² A prospective randomized double-masked study comparing flurbiprofen 0.03% and indomethacin 0.1% found that the 2 agents were equally effective in preventing miosis during cataract surgery.³³ Subsequent studies^{34,35} found that the use of indomethacin 0.1% and suprofen 1.0% significantly reduced pupil constriction during cataract surgery. Suprofen 1.0% was also approved by the FDA for the same indication in 1988. These medications are no longer commercially available in the United States.

The inhibition of intraoperative miosis is likely an effect of all NSAIDs. Roberts³⁶ compared diclofenac 0.1% and flurbiprofen 0.03% and found no differences in maintaining pupil dilation during phacoemulsification. A prospective randomized clinical study³⁷ found similar inhibition of miosis during cataract surgery for ketorolac 0.5% compared with flurbiprofen 0.03%. Maintenance of pupil dilation has also been seen with bromfenac 0.1%.³⁸

Various preoperative NSAID dosing regimens have been studied to examine their efficacy in maintaining pupil dilation. One study³⁹ evaluated the effectiveness of ketorolac 0.4% administered repeatedly starting 3 days, 1 day, or 1 hour before surgery. Starting 3 days before surgery resulted in less intraoperative miosis than starting 1 day or

1 hour before cataract surgery. Starting 1 day before surgery was significantly better at inhibiting miosis than the 1-hour preoperative dosing. Thus, there appears to be a role for starting topical NSAIDs at least 1 day before cataract surgery.

Although NSAIDs might inhibit surgically induced miosis, there is no evidence that they augment pupil dilation alone, and they should be used in conjunction with mydriatic agents.^{30,39,40} The benefit in using NSAIDs before cataract surgery, in particular in small-pupil cases, is that they inhibit the pupillary miosis that might develop from intraoperative iris manipulation and subsequent prostaglandin release and do not appear to serve a primary role in pupil dilation. Some studies^{41,42} have shown that the use of NSAIDs preoperatively might not provide additional benefit over the use of intraoperative epinephrine in the irrigating solution.

Despite acting upstream on the inflammatory cascade, it appears as though topical corticosteroids, such as prednisolone acetate 1.0%, administered before cataract surgery are less effective for maintaining mydriasis during surgery than the use of preoperative NSAIDs.⁴³

The use of preoperative topical atropine 1.0% was first studied by Bendel and Phillips⁴⁴ as a means to maximize cycloplegia during cataract surgery in IFIS patients. Sixteen patients taking tamsulosin were pretreated with atropine 1.0% twice daily starting 10 days before surgery. In the case series, 81% did not require intraoperative maneuvers to maintain pupil dilation throughout the case. However, a prospective study using atropine 1.0% 3 times daily starting 1 to 2 days before surgery⁴⁵ found that it was the least reliable means of managing small pupils related to IFIS; 58% required additional intraoperative strategies to maintain pupil dilation.

Narváez et al.⁴⁶ performed a prospective comparative study evaluating the mydriatic benefit of adding atropine 1.0% 3 times a day 1 day before a standard preoperative regimen of phenylephrine 2.5%, tropicamide 1.0%, and cyclopentolate 1.0%. They found that the addition of atropine 1.0% resulted in less mydriasis than the standard regimen alone. This appears to be consistent with other studies that found that doses of mydriatics started days before surgery might induce “pupil fatigue” and worsen dilation on the day of surgery.^{47,48} In addition, the adverse effects of using long-acting anticholinergic agents, such as atropine, including prolonged dilation and possible systemic side effects, likely outweigh any yet unproven benefit of enhanced pupil dilation.

As discussed, many patients are on topical and/or systemic agents that are known to cause pupillary miosis. There is no evidence to support having patients discontinue α -adrenergic inhibitors in small-pupil cases related to IFIS.^{45,49} Although surgeons might ask patients on miotics such as pilocarpine and those on prostaglandin analogs such as latanoprost to discontinue the drops before surgery, there are no scientific studies evaluating the effects of these various topical glaucoma medications on pupil size in cataract surgery. However, there might be a role for the

perioperative discontinuation of prostaglandin analogs before cataract surgery to reduce the risk for postoperative CME, although this is based largely on case reports with confounding risk factors.^{50–52}

INTRAOPERATIVE MANAGEMENT

Compounded Agents Used for Pupillary Mydriasis and Anesthesia During Cataract Surgery

Benefits of Compounded Intracameral Mydriatics Although compounded medications have inherent risks resulting from preparation and distribution, they can be extremely helpful adjunct agents for maintaining pupillary mydriasis and augmenting anesthesia during cataract surgery. The fast onset of action of these intracameral agents can decrease the time spent in the preoperative area by reducing or eliminating the need for mydriatic drops before surgery.

Intracameral mydriatics and analgesics have been used in cataract surgery since 2003.⁵³ The formulation was introduced in 2003 as a preservative-free mixture of cyclopentolate 0.1%, phenylephrine 1.5%, and lidocaine 1.0%. Cyclopentolate was later found not to have an additional mydriatic effect compared with phenylephrine 1.5% with lidocaine. Shugar^{54,B} popularized the use of buffered lidocaine to help with intraocular surgical pain as well as pupil dilation. He later added epinephrine in a pH-neutral solution to further augment dilation, resulting in a combination commonly known as epi-Shugarcaine. Lundberg and Behndig⁵⁵ later established the long-term safety of intracameral mydriatics relative to traditional topical agents for use in cataract surgery. They followed 45 patients for 6 years postoperatively and found no significant difference in the corrected visual acuity, IOP, pupil size, posterior capsule opacity, or neodymium:YAG rate between the groups. Endothelial cell loss, endothelial morphology, and corneal thickness were also equivalent.

Mydrane, a standardized ophthalmic combination of tropicamide 0.02%, phenylephrine 0.31%, and lidocaine 1.0%, was compared with a standard topical regimen in an international trial by the Intracameral Mydrane Study 2 Group.⁵⁶ Methods described in this international multicenter phase III prospective randomized trial involved the selected eye of 555 patients having phacoemulsification with IOL implantation receiving 200 μ L of Mydrane (Mydrane group) just after the first incision or a topical regimen of 1 drop each of tropicamide 0.5% and phenylephrine 10% repeated 3 times (reference group). Outcome measures included the ability to complete a capsulotomy, pupil size, and level of comfort at 5 points during surgery from the start of corneal incision to the subconjunctival injection of cefuroxime, and safety. Patients in the Mydrane group were significantly more comfortable before IOL insertion than those in the reference group. Surgeons also found IOL insertion less technically challenging in the Mydrane group than in the reference group.

Improved patient comfort and satisfaction have also been achieved with a combination of topical and intracameral agents used for mydriasis and anesthesia during cataract surgery.⁵⁷ In addition to pupil dilation, the use of an

intracameral preparation has the added benefit of increasing intraoperative patient comfort and decreasing the incidence of postoperative pain.⁵⁸ Finally, as mentioned, intracameral mydriatic use can assist with rapid pupil dilation in cases of miosis induced by femtosecond laser application during cataract surgery.²¹

At present, the 2 most commonly used compounded preparations include intracameral preservative-free lidocaine combined with preservative-free phenylephrine or epinephrine.

Disadvantages and Risks of Compounded Intracameral Mydriatics Although there are several benefits to intracameral mydriatic use, there are also limitations. The rate of pupil dilation is slower with the intracameral agents alone than with topical mydriatics. In a prospective comparative case series of 112 patients designed to evaluate the safety and efficacy of intracameral mydriatic use (lidocaine 1.0% and phenylephrine 1.5%) versus topical mydriatic use (phenylephrine 2.5% and tropicamide 1.0%) in pupil dilation for phacoemulsification surgery in Malaysians,⁵⁹ both methods were found to be safe and effective in dilating the pupil. The intracameral formulation, however, was found to have a slower onset of action.

Over the past several years, multiple cases and sentinel events of endophthalmitis and toxic anterior segment syndrome (TASS) have occurred as the result of improper compounding of intracameral, intravitreal, and systemic medications.^{60,C,D} Endophthalmitis associated with compounded intravitreal injections has been recorded in association with Avastin.^C Outbreaks of TASS have been recorded in association with intracameral lidocaine.⁶⁰

Despite these events involving compromised pharmaceutical compounding techniques, intracameral mydriatics and anesthetics, when prepared and administered in a well-controlled fashion, are an extremely helpful adjunct to cataract surgery, in particular in cases involving a small pupil.

Intraoperative Delivery of Phenylephrine 1.0% and Ketorolac 0.3%

In May 2014, Omidria (phenylephrine and ketorolac) was FDA-approved for use in adult patients having cataract surgery or IOL replacement to inhibit intraocular prostaglandin release and maintain pupil size by preventing miosis. In FDA-reviewed clinical studies,^E this drug was proven to be safe and well tolerated, providing direct, continuous intracameral delivery of NSAID and mydriatic/antimicrobial therapy during cataract surgery, improving the ability of pupils to remain the same size from the beginning of the cataract surgery to the end of the case.

The FDA phase 2b clinical trial was a 4-arm design comparing intraoperative delivery of Omidria versus phenylephrine 1.0% versus ketorolac 0.3% versus vehicle (a balanced salt solution). In this study, 6% of patients in the Omidria group developed a pupil diameter less than 6.0 mm at any time during surgery compared with 22% receiving phenylephrine alone, 35% receiving ketorolac alone, and 47% receiving vehicle alone. Two FDA phase 3

clinical trials each involved 400 patients in randomized double-masked placebo-controlled study with up to a 90-day follow-up. All patients, including placebo-treated patients, received standardized preoperative mydriatics and anesthetics (phenylephrine hydrochloride 2.5% plus tropicamide 1.0% 3 times in 30 minutes before surgery, and lidocaine or tetracaine for local anesthesia). Patients with a history of α -blocker use, PXF, or ocular trauma were excluded. Principal primary endpoints for both studies were met with statistical significance in terms of the change in pupil diameter over time and patient-reported ocular pain in the early postoperative period. In the 2 trials, 30% of patients treated with Omidria avoided a pupil diameter decrease of 2.5 mm or greater and up to 85% of patients never had a pupil smaller than 6.0 mm at any time during cataract surgery.⁶¹

Other studies^{58,62,F,G} found that Omidria compared to investigators' existing standards (eg, intracameral epinephrine) significantly reduced intraoperative complications (posterior capsule rupture, retained nuclear fragments, vitreous loss) 4-fold, decreased the need for pupil-expansion devices (eg, Malyugin ring), shortened surgical times, maintained pupil diameter in femtosecond laser-assisted procedures, and/or improved postoperative visual acuity.

In 2 studies,^{62,63} a statistically significant reduction in Malyugin ring use by 63% and 50% was shown in patients receiving Omidria compared with epinephrine control groups. Also, the surgical time was significantly reduced after adjusting for age in the Omidria group compared with the time in the epinephrine control group as follows: 15.6 versus 16.7 minutes in patients 78 to 92 years old and 10.2 versus 13.6 minutes in patients 30 to 64 years old.⁶³ Femtosecond laser-assisted cataract surgery cases indicate the pupil diameter over surgical timepoints is similar to that observed in traditional phacoemulsification cases using Omidria.^{E,F}

Mechanical Enlargement of the Small Pupil

A consistent and reliable method to handle a small pupil is the use of mechanical devices. Various devices have been developed to expand the pupil. Some devices, such as iris hooks and expansion rings, are inserted into the eye to mechanically maintain the maximum pupil size throughout the majority of the case. Other instruments are used to simply stretch the pupil and do not remain in the eye during the case.

Iris Hooks There are several varieties of iris hooks available, both disposable and reusable. Iris hooks are inserted through multiple small paracenteses. Care must be taken to create paracenteses that are far peripheral to allow insertion of the hooks near the level of the iris plane. If the paracentesis is too anterior, tenting of the iris can occur, which makes it difficult to insert instruments over the stretched pupillary border, placing the iris at risk for trauma. Surgeons can vary the number and location of iris hooks to optimize visualization. A variant on traditional placement described by Oetting and Omphroy⁶⁴ involves a diamond

configuration, with 1 hook placed under the main wound to allow ease of instrument entry into the anterior chamber and to facilitate subincisional cortical removal. In cases of suspicious zonular fiber integrity, several iris hooks can be placed in the area of zonular weakness to significantly retract the iris so direct visualization is possible. Capsule hooks can also be used in the case of zonular weakness to stabilize the capsular bag while retracting the iris peripherally.

Pupillary Expansion Rings The main advantage of rings over hooks is that they are inserted through the main corneal incision and do not require additional openings. The Malyugin ring is made of polypropylene (Prolene) designed with 4 scrolls with interconnections that run anterior to posterior between scrolls, creating 8 points of contact that engage the pupillary margin to evenly expand the pupil (Figure 3). There are 2 versions of the Malyugin ring, the original and version 2.0 (Microsurgical Technologies). The original ring is made of 4-0 polypropylene and can be inserted with an injector through a 2.2 mm or larger incision. The Malyugin ring 2.0 is more flexible because it is made of 5-0 polypropylene and can be injected through a 1.8 mm wound. The scrolls in the newer version are also larger, making it easier to engage the pupillary margin. Each of these versions comes in 6.25 mm and 7.00 mm diameters (ie, approximate dilation size when deployed). A purpose-designed manipulator is also available that facilitates initial placement of the scrolls as well as the disengagement and removal of the device. The injector system provides controlled deployment of the device and easy retrieval of the ring after placement of the IOL.

Additional advantages of the Malyugin ring over hooks include even stretching of the pupillary sphincter and rounded, blunt scrolls that can touch the anterior lens capsule without the risk for tearing the capsule. In a series of 30 patients, Chang⁶⁵ concluded that in eyes with IFIS, a common cause of intraoperative miosis, the device was a reliable and stable method for maintaining an adequate pupil diameter and was associated with minimal trauma to the iris. A helpful technique is to elevate the pupillary margin with an OVD in each area where the scroll will engage for ease of insertion and to not overly deepen the anterior chamber before insertion. Also, when removing the ring, the surgeon should engage the proximal scroll with the hook on the injector system, pull the ring into the injector until the lateral scrolls just touch, and then remove the device from the eye. The surgeon should not

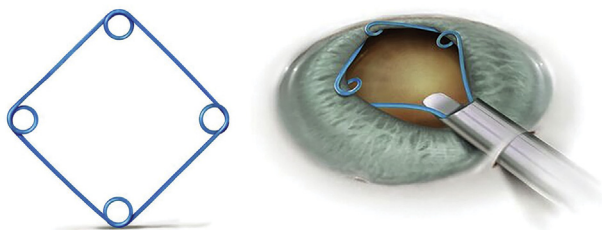


Figure 3. Malyugin ring.

attempt to retract the entire scroll into the injector because this can cause the ring to break, complicating its removal.

The Visitec I-Ring Pupil Expander (Beaver-Visitec International) is made of pliable polyurethane material that expands the pupil margin to a circular opening of 6.3 mm. It is inserted into the anterior chamber and engages the entire pupillary margin in a “channel” that has 4 positioning holes (Figure 4). A Sinsky hook can be used in these holes to help position the ring and engage the iris.

Pupil Expansion Devices The Assia pupil expander (APX Ophthalmology Ltd.)^H consists of 2 disposable devices that are inserted through 2 opposite 1.1 mm paracenteses, each located 90 degrees from the main corneal wound. The closed scissor-like devices are inserted through each paracentesis with a special forceps and slowly opened after the iris sphincter is engaged. The pupil expands to approximately 6.0 mm when both devices are opened. Benefits include not having to place the phacoemulsification or I/A tip over the devices because they are inserted through separate incisions. A disadvantage is the risk for anterior capsule tear if there is significant contact of the tip of the pupil expander with the anterior lens capsule.

Mechanical Stretching If the small pupil is stiff and fibrotic instead of floppy, mechanical stretching can be effective and essentially creates numerous tiny sphincterotomies. The pupil can be stretched with 2 instruments (eg, 2 Kuglen hooks) as described by Fry.¹ Two instruments are placed 180 degrees opposite each other at the pupil margin and then slowly pulled apart until the angle is reached (creating a cat’s-eye configuration). This is momentarily held and then released. The pupil can be stretched in the opposite direction as well, although this is not necessary. After the instruments are removed from the eye, OVD is used to expand the pupil symmetrically. Mechanical stretching can also be performed with 1 hand using a Beehler pupil dilator. This instrument is inserted through the main corneal incision and has 2 or 3 prongs, or “micro-fingers,” that extend forward to stretch the pupil simultaneously. An iris retractor on the shaft of the inserter gives countertraction to the micro-fingers. The minimum incision size for the 3-prong Beehler pupil dilator is 3.0 mm, while the 2-prong version can be inserted through a 2.5 mm wound. Stretching the pupil might be more traumatic to the iris sphincter than using a ring and also does not maintain mechanical control of the pupil margin during the fluidics that occur with phacoemulsification and cortical removal, allowing the iris to billow and become more floppy.

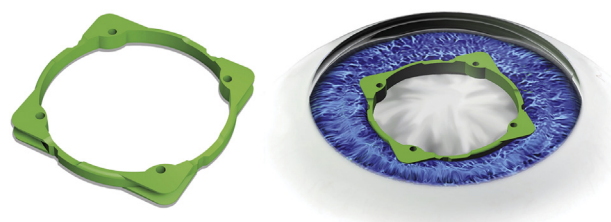


Figure 4. Visitec I-Ring pupil expander.

Other less commonly used pupillary expansion devices include the 5S iris ring (Morcher GmbH), Perfect Pupil (Milvella Ltd.), Graether expander (Eagle Vision, Inc.), Clarke ring, and the Siepser ring.

POSTOPERATIVE CARE

As discussed, patients with small pupils are at higher risk for delayed healing, corneal edema, uveitis, CME, and elevated IOP. This might be the result of any combination of pupil expansion methods, a longer surgical time, and unanticipated surgical complications, such as vitreous loss and retained lens material. In addition, even in the uneventful case, preexisting conditions such as diabetes and uveitis might predispose these patients to increased postoperative inflammation and its sequelae. As a result, based on the severity of risk, the surgeon might consider extending the postoperative course of antiinflammatory treatment.

By anticipating these issues and advising patients in advance of their surgery, the patient's perception of a suboptimum outcome shifts from an unanticipated complication to an anticipated side effect related to a preexisting condition. This preoperative discussion opens the door to educating the patient about the possibility of delayed visual recovery and to the potential need for frequent and/or prolonged eyedrop regimens or even subconjunctival or sub-Tenon injections in rare situations.

DISCUSSION

Management of patients with small pupils begins preoperatively with the identification of risk factors, patient counseling, surgical planning, and the use of preoperative NSAIDs. It continues during the surgical process through the use of intracameral dilating/anesthetic agents and mechanical dilation techniques. Finally, postoperative management might be customized in certain cases with the alteration of postoperative eyedrop regimens. Fortunately, there are many points during this process at which we can intervene as surgeons to reduce the patient's risk and make the surgery technically easier, thus maximizing postoperative outcomes and patient satisfaction.

REFERENCES

- Ratra V, Lam DSC. Small pupil—big problem. A management algorithm. *Asia Pac J Ophthalmol* 2015; 4:131–133. Available at: https://journals.lww.com/apjoo/Fulltext/2015/05000/Small_Pupil_Big_Problem__A_Management_Algorithm.2.aspx. Accessed May 27, 2018
- Hashemi H, Seyedian MA, Mohammadpour M. Small pupil and cataract surgery. *Curr Opin Ophthalmol* 2015; 26:3–9
- Bonnell LN, SooHoo JR, Seibold LK, Lynch AM, Wagner BD, Davidson RS, Taravella MJ. One-day postoperative intraocular pressure spikes after phacoemulsification cataract surgery in patients taking tamsulosin. *J Cataract Refract Surg* 2016; 42:1753–1758
- Flach AJ. The incidence, pathogenesis and treatment of cystoid macular edema following cataract surgery. *Trans Am Ophthalmol Soc* 1998; 96:557–634. Available at: <http://www.pubmedcentral.nih.gov/picrender.fcgi?artid=1298410&blobtype=pdf>. Accessed May 27, 2018
- Vasavada A, Singh R. Phacoemulsification in eyes with a small pupil. *J Cataract Refract Surg* 2000; 26:1210–1218
- Akman A, Yilmaz G, Oto S, Akova YA. Comparison of various pupil dilatation methods for phacoemulsification in eyes with a small pupil secondary to pseudoexfoliation. *Ophthalmology* 2004; 111:1693–1698
- Masket S. Cataract surgery complicated by the miotic pupil. In: Buratto L, Osher RH, Masket S, eds. *Cataract Surgery in Complicated Cases*. Thorfare NJ, Slack, 2000; 131–135
- Zavodni ZJ, Meyer JJ, Kim T. Clinical features and outcomes of retained lens fragments in the anterior chamber after phacoemulsification. *Am J Ophthalmol* 2015; 160:1171–1175
- Naumann GOH, Schlotzer-Schrehardt U, Kuchle M. Pseudoexfoliation syndrome for the comprehensive ophthalmologist; intraocular and systemic manifestations. *Ophthalmology* 1998; 105:951–968
- Asano N, Schlotzer-Schrehardt U, Naumann GOH. A histopathologic study of iris changes in pseudoexfoliation syndrome. *Ophthalmology* 1995; 102:1279–1290
- Carpel EF. Pupillary dilation in eyes with pseudoexfoliation syndrome. *Am J Ophthalmol* 1988; 105:692–694
- Amarsson A, Damji KF, Sverrisson T, Sasaki H, Jonasson F. Pseudoexfoliation in the Reykjavik Eye Study: prevalence and related ophthalmological variables. *Acta Ophthalmol Scand* 2007; 85:822–827. Available at: <https://onlinelibrary.wiley.com/doi/epdf/10.1111/j.1600-0420.2007.01051.x>. Accessed May 27, 2018
- Chu CJ, Dick AD, Johnston RL, Yang YC, Denniston AK, for the UK Pseudoexfoliation Macular Edema Study Group. Cataract surgery in uveitis: a multicentre database study. *Br J Ophthalmol* 2017; 101:1132–1137
- Smith SA, Smith SE. Evidence for a neuropathic aetiology in the small pupil of diabetes mellitus. *Br J Ophthalmol* 1983; 67:89–93. Available at: <http://www.ncbi.nlm.nih.gov/pmc/articles/PMC1039972/pdf/brjophthal00158-0017.pdf>. Accessed May 27, 2018
- Huber MJE, Smith SA, Smith SE. Mydriatic drugs for diabetic patients. *Br J Ophthalmol* 1985; 69:425–427. Available at: <http://www.ncbi.nlm.nih.gov/pmc/articles/PMC1040620/pdf/brjophthal00138-0029.pdf>. Accessed May 27, 2018
- Zaczek A, Zetterström C. Cataract surgery and pupil size in patients with diabetes mellitus. *Acta Ophthalmol Scand* 1997; 75:429–432. Available at: <http://www3.interscience.wiley.com/cgi-bin/fulltext/122407159/PDFSTART>. Accessed May 27, 2018
- Chakrabarti A, Singh S, Krishnadas R. Phacoemulsification in eyes with white cataract. *J Cataract Refract Surg* 2000; 26:1041–1047
- Kránitz K, Takacs A, Miháitz K, Kovács I, Knorz MC, Nagy ZZ. Femtosecond laser capsulotomy and manual continuous curvilinear capsulorhexis parameters and their effects on intraocular lens centration. *J Refract Surg* 2011; 27:558–563
- Jun JH, Hwang KY, Chang SD, Joo C-K. Pupil-size alterations induced by photodisruption during femtosecond laser-assisted cataract surgery. *J Cataract Refract Surg* 2015; 41:278–285
- Schultz T, Joachim SC, Stellbogen M, Dick HB. Prostaglandin release during femtosecond laser-assisted cataract surgery: main inducer. *J Refract Surg* 2015; 31:71–81. Available at: http://scholar.google.com/scholar_url?url=https://www.researchgate.net/profile/H_Dick/publication/273152684_Prostaglandin_Release_During_Femtosecond_Laser-Assisted_Cataract_Surgery_Main_Inducer/links/56cfc5c1708ae059e375971c3/Prostaglandin-Release-During-Femtosecond-Laser-Assisted-Cataract-Surgery-Main-Inducer.pdf&hl=en&sa=X&scisig=AAgBFm3JyMVBfGEj03WY3ifjmQTVcLGJHQ&nossl=1&oi=scholar. Accessed May 27, 2018
- Nagy ZZ, Takacs AI, Filkorn T, Kránitz K, Gyenes A, Juhász E, Sándor GL, Kovacs I, Juhász T, Slade S. Complications of femtosecond laser-assisted cataract surgery. *J Cataract Refract Surg* 2014; 40:20–28
- Kremer M, Baikoff G, Charbonnel B. The release of prostaglandins in human aqueous humour following intraocular surgery. Effect of indomethacin. *Prostaglandins* 1982; 23:695–702
- Chang DF, Campbell JR. Intraoperative floppy iris syndrome associated with tamsulosin. *J Cataract Refract Surg* 2005; 31:664–673
- Bent S, Kane C, Shinohara K, Neuhaus J, Hudes ES, Goldberg H, Alvins AL. Saw palmetto for benign prostatic hyperplasia. *N Engl J Med* 2006; 354:557–566. Available at: <https://www.nejm.org/doi/pdf/10.1056/NEJMOa053085>
- Yeu E, Grosztern R. Saw palmetto and intraoperative floppy-iris syndrome. *J Cataract Refract Surg* 2007; 33:927–928
- Saw palmetto. Review of Natural Products. Facts and Comparisons 4.0. St. Louis, MO, Wolters Kluwer Health, Inc., 2009
- Gogate P, Wood M. Recognising 'high-risk' eyes before cataract surgery. *Community Eye Health* 2008; 21:12–14. Available at: https://www.ncbi.nlm.nih.gov/pmc/articles/PMC2377383/pdf/ceh_21_65_012.pdf
- Öztürk F, Kurt E, İnan ÜÜ, İlker SS. The efficacy of 2.5% phenylephrine and flurbiprofen combined in inducing and maintaining pupillary dilatation during cataract surgery. *Eur J Ophthalmol* 2000; 10:144–148
- Tanner V, Casswell AG. A comparative study of the efficacy of 2.5% phenylephrine and 10% phenylephrine in pre-operative mydriasis for routine

- cataract surgery. *Eye* 1996; 10:95–98. Available at: <http://www.nature.com/eye/journal/v10/n1/pdf/eye199615a.pdf>. Accessed May 27, 2018
30. Duffin RM, Camras CB, Gardner SK, Pettit TH. Inhibitors of surgically induced miosis. *Ophthalmology* 1982; 89:966–978; discussion by SM Poddos, 978–979
 31. Kim SJ, Flach AJ, Jampol LM. Nonsteroidal anti-inflammatory drugs in ophthalmology. *Surv Ophthalmol* 2010; 55:108–133
 32. Keates RH, McGowan KA. Clinical trial of flurbiprofen to maintain pupillary dilation during cataract surgery. *Ann Ophthalmol* 1984; 16:919–921
 33. Gimbel H, Van Westenbrugge J, Cheetham JK, DeGryse R, Garcia CG. Intraocular availability and pupillary effect of flurbiprofen and indomethacin during cataract surgery. *J Cataract Refract Surg* 1996; 22:474–479
 34. Stark WJ, Fagadau WR, Stewart RH, Crandall AS, deFaller JM, Reaves TA Jr, Klein PE. Reduction of pupillary constriction during cataract surgery using suprofen. *Arch Ophthalmol* 1986; 104:364–366
 35. Keulen-De Vos HCJ, Van Rij G, Renardel De Lavalette JCG, Jansen JTG. Effect of indomethacin in preventing surgically induced miosis. *Br J Ophthalmol* 1983; 67:94–96. Available at: <http://www.ncbi.nlm.nih.gov/pmc/articles/PMC1039973/pdf/brjophthal00158-0022.pdf>. Accessed May 27, 2018
 36. Roberts CW. Comparison of diclofenac sodium and flurbiprofen for inhibition of surgically induced miosis. *J Cataract Refract Surg* 1996; 22:780–787
 37. Solomon KD, Turkalj JW, Whiteside SB, Stewart JA, Apple DJ. Topical 0.5% ketorolac vs 0.03% flurbiprofen for inhibition of miosis during cataract surgery. *Arch Ophthalmol* 1997; 115:1119–1122
 38. Ohara K, Ohkubo A, Miyakubo T, Miyamoto H, Nezu N. [Prevention of miosis during cataract surgery by topical bromfenac sodium]. [Japanese]. *Rinsho Ganka* 2004; 58:1325–1328
 39. Donnerfeld ED, Perry HD, Wittppenn JR, Solomon R, Nattis A, Chou T. Preoperative ketorolac tromethamine 0.4% in phacoemulsification outcomes: pharmacokinetic-response curve. *J Cataract Refract Surg* 2006; 32:1474–1482
 40. Drews RC, Katsev DA. Ocufen and pupillary dilation during cataract surgery. *J Cataract Refract Surg* 1989; 15:445–448
 41. Shaikh MY, Mars JS, Heaven CJ. Prednisolone and flurbiprofen drops to maintain mydriasis during phacoemulsification cataract surgery. *J Cataract Refract Surg* 2003; 29:2372–2377
 42. Gimbel HV. The effect of treatment with topical nonsteroidal anti-inflammatory drugs with and without intraoperative epinephrine on the maintenance of mydriasis during cataract surgery. *Ophthalmology* 1989; 96:585–588
 43. Dubé P, Boisjoly HM, Bazin R, Chamberland G, Laughrea PA, Dubé I. Comparison of prednisolone acetate and indomethacin for maintaining mydriasis during cataract surgery. *Can J Ophthalmol* 1990; 25:234–238
 44. Bendel RE, Phillips MB. Preoperative use of atropine to prevent intraoperative floppy-iris syndrome in patients taking tamsulosin. *J Cataract Refract Surg* 2006; 32:1603–1605
 45. Chang DF, Osher RH, Wang L, Koch DD. Prospective multicenter evaluation of cataract surgery in patients taking tamsulosin (Flomax). *Ophthalmology* 2007; 114:957–964
 46. Narváez J, Kronberg BP, Park H, Zumwalt JR, Wong B, Bacon G, Rauser M, Hoehn AS, Eisman H, Zimmerman G. Pupil dilation using a standard cataract surgery regimen alone or with atropine 1.0% pretreatment; prospective comparative evaluation. *J Cataract Refract Surg* 2010; 36:563–567
 47. Power WJ, Hope-Ross M, Mooney DJ. Preoperative pupil fatigue. *J Cataract Refract Surg* 1992; 18:306–309
 48. McCormack DL. Reduced mydriasis from repeated doses of tropicamide and cyclopentolate. *Ophthalmic Surg* 1990; 21:508–512
 49. Chang DF, Braga-Mele R, Marmalis N, Masker S, Miller KM, Nichamin LD, Packard RB, Packer M, for the ASCRS Cataract Clinical Committee. ASCRS white paper: Clinical review of intraoperative floppy-iris syndrome. *J Cataract Refract Surg* 2008; 34:2153–2162. Available at: <http://www.ascrs.org/sites/default/files/resources/JCRS%20IFIS%20White%20Paper%202012-08.pdf>. Accessed May 27, 2018
 50. Ayyala RS, Cruz DA, Margo CE, Harman LE, Pautler SE, Misch DM, Mines JA, Richards DW. Cystoid macular edema associated with latanoprost in aphakic and pseudophakic eyes. *Am J Ophthalmol* 1998; 126:602–604
 51. Yeh PC, Ramanathan S. Latanoprost and clinically significant cystoid macular edema after uneventful phacoemulsification with intraocular lens implantation. *J Cataract Refract Surg* 2002; 28:1814–1818
 52. Schumer RA, Camras CB, Mandahl AK. Latanoprost and cystoid macular edema: is there a causal relation? *Curr Opin Ophthalmol* 2000; 11:94–100. Available at: http://www.hvglaucoma.com/pdfs/schumer_magdahl_camras2000.pdf. Accessed May 27, 2018
 53. Behndig A, Eriksson A. Evaluation of surgical performance with intracameral mydriatics in phacoemulsification surgery. *Acta Ophthalmol Scand* 2004; 82:144–147. Available at: <http://www3.interscience.wiley.com/cgi-bin/fulltext/118808583/PDFSTART>. Accessed May 27, 2018
 54. Shugar JK. Use of epinephrine for IFIS prophylaxis [letter]. *J Cataract Refract Surg* 2006; 32:1074–1075
 55. Lundberg B, Behndig A. Intracameral mydriatics in phacoemulsification cataract surgery – a 6-year follow-up. *Acta Ophthalmol* 2013; 91:243–246. Available at: <http://onlinelibrary.wiley.com/doi/10.1111/j.1755-3768.2011.02378.x/pdf>. Accessed May 27, 2018
 56. Labetoulle M, Findl O, Malecaze F, Alió J, Cochener B, Lobo C, Lazreg S, Hartani D, Colin J, Tassignon M-J, Behndig A, on behalf of the Intracameral Mydrane Study 2 Group. Evaluation of the efficacy and safety of a standardised intracameral combination of mydriatics and anaesthetics for cataract surgery. *Br J Ophthalmol* 2016; 100:976–985. Available at: <https://www.ncbi.nlm.nih.gov/pmc/articles/PMC4941138/pdf/bjophthalmol-2015-307587.pdf>. Accessed May 27, 2018
 57. Fernandes MBC, de Souza RVF, Vasconcelos GC, Ribeiro KG, Andrade BB, Fernandes CR. Assessing patient satisfaction with cataract surgery under topical anesthesia supplemented by intracameral lidocaine combined with sedation. *Arq Bras Oftalmol* 2013; 76:345–349. Available at: <http://www.scielo.br/pdf/abo/v76n6/05.pdf>. Accessed May 27, 2018
 58. Donnerfeld ED, Whitaker JS, Jackson MA, Wittppenn J. Intracameral mydriatics versus topical mydriatics in pupil dilation for phacoemulsification cataract surgery. *J Cataract Refract Surg* 2017; 43:597–605. Available at: [https://www.jcrjournal.org/article/S0886-3350\(17\)30253-5/pdf](https://www.jcrjournal.org/article/S0886-3350(17)30253-5/pdf). Accessed May 27, 2018
 59. Lay Suan AL, Hamzah JC, Ken TS, Mansurali VN. Intracameral mydriatics versus topical mydriatics in pupil dilation for phacoemulsification cataract surgery. *J Cataract Refract Surg* 2017; 43:1031–1035
 60. Bielory BP, Shariff A, Hussain RM, Bermudez-Magner JA, Dubovy SR, Donaldson KE. Toxic anterior segment syndrome: inadvertent administration of intracameral lidocaine 1% and phenylephrine 2.5% preserved with 10% benzalkonium chloride during cataract surgery. *Cornea* 2017; 36:621–624
 61. Hovanesian JA, Sheppard JD, Trattler WB, Gayton JL, Malhotra RP, Schaaf DT, Ng E, Dunn SH. Intracameral phenylephrine and ketorolac during cataract surgery to maintain intraoperative mydriasis and reduce postoperative ocular pain: integrated results from 2 pivotal phase 3 studies. *J Cataract Refract Surg* 2015; 41:2060–2068. erratum, 2016; 42:951. Available at: [http://www.jcrjournal.org/article/S0886-3350\(15\)01183-9/pdf](http://www.jcrjournal.org/article/S0886-3350(15)01183-9/pdf). Accessed May 27, 2018. Erratum available at: [http://www.jcrjournal.org/article/S0886-3350\(16\)30143-2/pdf](http://www.jcrjournal.org/article/S0886-3350(16)30143-2/pdf)
 62. Bucci FA Jr, Michalek B, Fluet AT. Comparison of the frequency of use of a pupil expansion device with and without an intracameral phenylephrine and ketorolac injection 1%/0.3% at the time of routine cataract surgery. *Clin Ophthalmol* 2017; 11:1039–1043. Available at: <https://www.ncbi.nlm.nih.gov/pmc/articles/PMC5460648/pdf/oph-11-1039.pdf>. Accessed May 27, 2018
 63. Visco D. Effect of phenylephrine/ketorolac on iris fixation ring use and surgical times in patients at risk for intraoperative miosis. *Clin Ophthalmol* 2018; 12:301–305. Available at: <https://www.ncbi.nlm.nih.gov/pmc/articles/PMC5804732/pdf/oph-12-301.pdf>. Accessed May 27, 2018
 64. Oetting TA, Omphroy LC. Modified technique using flexible iris retractors in clear corneal surgery. *J Cataract Refract Surg* 2002; 28:596–598
 65. Chang DF. Use of Malyugin pupil expansion device for intraoperative floppy-iris syndrome: results in 30 consecutive cases. *J Cataract Refract Surg* 2008; 34:835–841

OTHER CITED MATERIAL

- A. Donnerfeld E, Gupta A, Morris M, Zilos G, Robilotto R, “The Effect of Cataract Surgery on the Pupil Light Response,” presented as a poster at the XXXI Congress of the European Society of Cataract and Refractive Surgeons, Amsterdam, the Netherlands, October 2013. Abstract available at: <http://www.esors.org/amsterdam2013/programme/posters-details.asp?id=19149>. Accessed May 27, 2018
- B. Shugar JK. Intracameral epinephrine for IFIS prophylaxis. *Cataract & Refractive Surgery Today*. September 2006, pages 72–74. Available at: https://crstoday.com/articles/2006-sep/crst0906_14.html. Accessed May 27, 2018
- C. Pollack A. Five more reports of Avastin injections causing blindness. *New York Times*, September 1, 2011. Available at: <https://www.nytimes.com/2011/09/02/business/more-reports-of-avastin-causing-blindness.html>. Accessed May 27, 2018
- D. Eichenwald K. Killer pharmacy: inside a medical mass murder case. *Newsweek* April 16, 2015. Available at: <http://www.newsweek.com/2015/04/24/inside-one-most-murderous-corporate-crimes-us-history-322665.html>. Accessed May 27, 2018

- E. Walter K, Delwadia N, "Miosis Prevention in Femtosecond-Assisted Cataract Surgery Using a Continuous Infusion of Phenylephrine and Ketorolac," presented at the annual meeting of the American Society of Cataract and Refractive Surgery, Washington, DC, USA, April 2018
- F. Gayton J, "Effect of Early Phenylephrine and Ketorolac Injection 1%/0.3% (Omidria) Usage on Pupil Diameter in Traditional and Femto-Assisted Cataract Surgery," presented at the 15th International Congress on Vision Science and Eye, London, United Kingdom, August 2017. Abstract available at: <https://www.scitechnol.com/conference-abstracts-files/2324-8599-C1-003-003.pdf>. Accessed May 27, 2018
- G. Matossian C, "Clinical and Economic Outcomes in Cataract Surgery Using Phenylephrine 1.0%-ketorolac 0.3% in a Real-World Setting," presented at the annual meeting of the American Society of Cataract and Refractive Surgery, Washington, DC, USA, April 2018
- H. Assia EI. Assia pupil expander useful for small pupils in routine and complex cataract surgeries. *Ocular Surgery News U.S.* ed. April 10, 2017. Available at: <https://www.healio.com/ophthalmology/cataract-surgery/news/print/ocular-surgery-news/%7B0803d79e-7d29-452b-84c4-e4f4c3babc9c>

[%7D/assia-pupil-expander-useful-for-small-pupils-in-routine-and-complex-cataract-surgeries](#). Accessed May 27, 2018

- I. Fry L. Pupil Stretching. *Video J Cataract Refract Surg* 1995; XI (1)

Disclosures: *Dr. Donaldson is a consultant to Alcon Laboratories, Inc., Allergan Inc., Bausch & Lomb, Inc., Bio-Tissue, Inc., Johnson & Johnson, Lumenis, Inc., Omeros Corp., Shire, Sun Pharmaceutical Industries Ltd, and Tearlab Corp. Dr. Jackson is a consultant to Omeros Corp. and APX Ophthalmology Ltd. Dr. Kieval is a consultant to Abbott Medical Optics, Inc., Alcon Laboratories, Inc., Allergan, Inc., Eyepoint Pharmaceuticals, Inc., and Sun Pharmaceutical Industries Ltd. Dr. Paterson receives personal fees from Omeros Corp. Dr. Hamilton is a consultant to Abbott Medical Optics, Inc., Alcon Laboratories, Inc., Carl Zeiss Meditec AG, and Johnson & Johnson. No other authors has a financial or proprietary interest in any material or method mentioned.*