

Comparison of iris-fixated foldable lens and scleral-fixated foldable lens implantation in eyes with insufficient capsular support

Han Zhang¹, Jun Zhao², Li-Jun Zhang³, Jing Liu⁴, Yuan Liu⁴, Wei Song¹, Qing-Fen Tian¹, Qi Wang², David-Rex Hamilton⁵

¹Department of Ophthalmology, the Second Hospital of Shandong University, Jinan 250033, Shandong Province, China

²Department of Ophthalmology, General Hospital of Liaohe Oil Field, Panjin 124010, Liaoning Province, China

³Refractive Center, Third Hospital Affiliated of Dalian Medical University, Dalian 116033, Liaoning Province, China

⁴Department of Ophthalmology, Zibo Kangming Ophthalmology Hospital, Zibo 255025, Shandong Province, China

⁵UCLA Laser Refractive Center, Los Angeles, CA 90095, USA

Correspondence to: Han Zhang. Department of Ophthalmology, the Second Hospital of Shandong University, No 247, Beiyuan Avenue, Jinan 250033, Shandong Province, China. han1_zhang@163.com; David-Rex Hamilton. Jules Stein Eye Institute 100 Stein Plaza, UCLA Los Angeles, CA 90095, USA. HamiltonDavidRex@163.com

Received: 2015-07-29 Accepted: 2015-09-25

Abstract

• **AIM:** To compare the outcomes of vision using two different intraocular lens (IOL) replacement techniques, iris-fixated foldable intraocular lens (IF-IOL) and scleral-fixated foldable intraocular lens (SF-IOL) in patients with insufficient capsular support.

• **METHODS:** Total 63 eyes (62 patients) with insufficient posterior capsule support underwent replacement of IF-IOL or SF-IOL between January 2008 and August 2011. Outcome measures included changes in visual acuity, slit lamp examination, refractive indices and corneal curvatures.

• **RESULTS:** The mean improvement of uncorrected visual acuity (UCVA) was greater in IF-IOL group compared to the SF-IOL group ($0.43 \text{ D} \pm 0.19 \text{ D}$ vs $0.35 \text{ D} \pm 0.18 \text{ D}$, $P < 0.05$). Moreover, 12 (38.71%) eyes in IF-IOL group and 4 (12.50%) in SF-IOL group had a higher postoperative UCVA than preoperative best corrected visual acuity (BCVA) while 9 (29.03%) eyes in IF-IOL

group and 18 (56.25%) in SF-IOL group had a lower postoperative UCVA than preoperative BCVA. The myopic mean manifest sphere and mean cylinder magnitude were lower in the IF-IOL group than that in the SF-IOL group ($-0.47 \text{ D} \pm 0.58 \text{ D}$ vs $0.50 \text{ D} \pm 0.43 \text{ D}$, $P < 0.01$; $0.84 \text{ D} \pm 0.53 \text{ D}$ vs $1.23 \text{ D} \pm 0.70 \text{ D}$, $P < 0.05$). No difference of corneal astigmatism and surgically induced astigmatism was found between the two groups. In addition, fewer complications were observed in IF-IOL eyes.

• **CONCLUSION:** IF-IOL implantation can give a significant improvement in vision with fewer complications than SF-IOL in patients with insufficient capsular support.

• **KEYWORDS:** iris-fixated foldable intraocular lens; scleral-fixated foldable intraocular lens; visual acuity; refraction

DOI:10.18240/ijo.2016.11.11

Zhang H, Zhao J, Zhang LJ, Liu J, Liu Y, Song W, Tian QF, Wang Q, Hamilton DR. Comparison of iris-fixated foldable lens and scleral-fixated foldable lens implantation in eyes with insufficient capsular support. *Int J Ophthalmol* 2016;9(11):1608–1613

INTRODUCTION

Modern cataract surgery requires to keep an intact posterior capsule and to implant a posterior chamber intraocular lens (PCIOL) inside of the capsular bag^[1]. However, it is hard to conduct because the thinnest part of the capsule is located at the posterior pole. A PCIOL implantation in the ciliary sulcus is suggested to perform, when the ruptured posterior capsule occurred^[2]. In addition, surgical treatment for cataract surgery carries a risk for serious complications such as intraocular lens (IOL) nucleus drop or PCIOL dislocation, either spontaneously or secondary to trauma^[3]. As a result, pars plana vitrectomy is required for treatment of these complications.

Special methods were required for correction of aphakia in individuals who were in the absence of capsular support for ciliary sulcus PCIOL implantation. Various IOL methods have been reported to correct aphakia, such as angle supported anterior chamber intraocular lenses (ACIOLs),

sclera fixation posterior chamber intraocular lenses (SF-PCIOL), and iris claw anterior chamber intraocular lenses (IC-ACIOLs) [4-6]. Due to the requirement of considerable operative time and the association with complications (IOL tilt, decentration, and displacement into the vitreous cavity, choroidal hemorrhage, retinal detachment, CME and conjunctival erosion secondary to use of trans-scleral sutures), difficulties will be presented when performing the SF-PCIOL implantation [7-8].

IC-ACIOLs were first introduced in 1986 by Fechner and Worst to correct myopia, but were later used to correct aphakia [9]. The lens was fixated to the mid peripheral iris, where the iris is less vascularized and less reactive [10]. This feature makes the implantation easy to process. However, unfoldable lens and large incision are the major disadvantages of the lens [11]. As an alternative choice in PCIOL implantation, sutured iris-fixated foldable intraocular lens (IF-IOL), introduced by McCannel [12] in 1976, was proposed to apply in patients underwent corneal transplantation or intracapsular cataract extraction in the absence of capsular support. Recent studies have shown that IF-IOL was efficient in patients with insufficient capsular support [13]. Although the size of the incision is large, suture IF-IOL is simple and easy to perform. In 2010, Zandian *et al* [14] used an acrylic 3-piece PCIOL through a small clear corneal incision with haptics secured in knots and they claimed no need for the IOL capture. This technique gave us an insight into modification of suture IF-IOL.

In the present study, to compare the outcome of vision in patients with insufficient capsular support, two different IOL replacement techniques IF-IOL and scleral-fixated foldable intraocular lens (SF-IOL) were performed. Findings of this study may provide an alternative for treatment of eyes with insufficient capsular support.

SUBJECTS AND METHODS

Subjects A total of 62 patients (63 eyes) with aphakia were recruited in the study from January 2008 to August 2011. Before the surgery, they were randomly divided into sutured IF-IOL [group A, $n=31$ patients (31 eyes)] and SF-IOL group [group B, $n=31$ patients (32 eyes)] by random block design with Excel 2010. Firstly, the patients were numbered from 1 to 62 and these numbers were input into the Excel. Then randomization was generated by the function of inserting random number and compositor. Those with odd end figures of the random numbers were divided into the IF-IOL group, and the rest with even number of the random numbers were divided into the SF-IOL group. The study protocol was approved by the Ethics Committee of our hospital and the written informed consent was obtained from all the patients.

Patients were included or excluded according to a previous description [15]. Briefly, inclusion criteria were patients with 1)

monocular surgical aphakia with no capsular support; 2) no evidence of iris atrophy; 3) presence of a complete iris or slight iridoschisis that does not affect IOL implant; 4) undilated pupil ≤ 5 mm in diameter, and corrected visual acuity (VA) ≥ 0.1 . Exclusion criteria were patients with 1) severe corneal trauma; 2) significant irregular astigmatism (> 2 D corneal astigmatism); 3) evident traumatic posterior segment; 4) iridoschisis > 2 o'clock; 4) corrected VA < 0.1 .

All patients underwent complete preoperative ophthalmologic evaluation including best corrected visual acuity (BCVA), and subjective refraction. The measurements taken were as follows: 1) slit-lamp examination with emphasis on position of previous surgical peripheral iridectomy and pupil; 2) keratometry and A scan; 3) A constant (117.0) and SRK/T formula used for IOL power calculation; 4) retinal evaluation with 90 D and indirect ophthalmoscopy; 5) Goldmann applanation tonometry. Eyes which received IOL implantation were targeted for a postoperative refraction of 0 to -0.50 diopters (D). The 3 piece hydrophobic acrylic IOL (Alcon, MA60AC) was used in these patients.

Sutured Iris -fixated Foldable Intraocular Lens Implantation

All operations were performed by the same surgeon. The pupil contraction was induced preoperatively by pilocarpine 1% (Bausch & Lomb Freda Corp, China). Under topical anesthesia in intracameral, retrobulbar and general anesthesia, a 3.0 mm clear corneal incision and an auxiliary incision were made at 11 o'clock position and 2 o'clock position, respectively. Anterior vitrectomy was performed to remove the vitreous from anterior chamber after injection with viscoelastic agent. The foldable IOL was inserted by placing haptics at the posterior of the iris, and make sure the optics located in the anterior part of papillary border. The haptics was sutured using a 10-0 polypropylene (PC-9, Alcon Corp, USA) suture passed through the peripheral cornea, back through iris, across the posterior of the IOL haptics, and out from the iris and peripheral cornea (Figure 1A, 1C). A slipknot was then made to make the IOL implant into the correct position (Figure 1B, 1D). Then the optics was implanted on the posterior of pupil (Figure 1E). After adjustment of IOL to the correct position (Figure 1F), both sides of the slipknots were unlocked and the sutures were removed from the incision of cornea (Figure 1G). Finally, the IOL was fixated to the periphery of the iris.

Sutured Sclera -fixated Foldable Intraocular Lens Implantation

A combination of 0.5% phenylephrine and 0.5% tropicamide (Wuhan Wujing Corp., Wuhan, China) was used preoperatively to achieve adequate papillary dilation. A 3.2 mm clear corneal incision was made at the 11 o'clock position, and then two diametrically opposed limbal-based partial-thickness triangular scleral flaps were prepared along with the horizontal meridians at 3 o'clock and 9 o'clock, respectively. The straight needle of 10-0

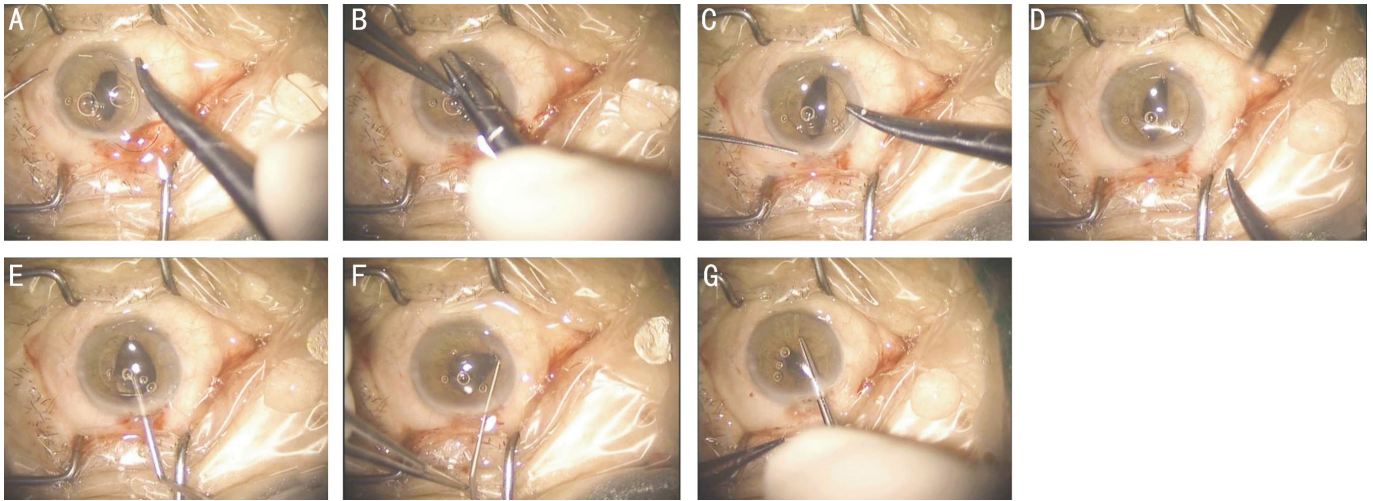


Figure 1 The surgery process of iris-fixated foldable lens implantation A: The foldable IOL was implanted into the posterior of iris and the optics was located in the anterior of pupil. A 10-0 polypropylene suture was passed through the peripheral cornea, back through iris, across the posterior part of the IOL haptics, out the iris and peripheral cornea; B: A slipknot was made on the cornea by connecting the extraocular suture to make sure there was enough room for IOL; C: The second part of IOL was implanted and sutured with the similar method described as A; D: A slipknot was made as described as B; E: The optics was implanted on the posterior part of pupil; F: Adjustment of the position of IOL; G: Unlock the slipknot and removed the suture from the incision of cornea. A knot was made by connecting the end of suture, and the IOL was fixed at the posterior part of the iris.

polypropylene (AUM-5 & SC-5, Alcon Corp) suture was passed *via* a paracentesis through the eye under the scleral flap 1.5 mm posterior to the limbus. On the opposite end, a 27 G needle carrying the suture was inserted into the limbus under the scleral flap and pulled out through the corneal incision. The suture was then cut off by a scissor. Afterwards, the cutting ends were tied to 2 haptics at the site corresponding to the maximum spread of each haptic of a foldable IOL. The IOL was implanted into the posterior chamber and fixed by the suture at 3 and 9 o'clock position under the sclera flap 1.5 posterior to the limbus.

Postoperative Follow-up Patients were followed-up at 3mo, 6mo, 1y and 2y. The data at 3mo were presented in this study. Retinoscopy was used to determine the manifest refraction. Postoperative uncorrected visual acuity (UCVA) and preoperative BCVA were detected. Tonometry was measured by Goldmann applanation tonometer. Corneal astigmatism measured by manual keratometry was assessed according to the differences between curvatures of the corneal steep and flat axes. Preoperative and postoperative keratometry readings were used for vector analysis and surgically induced astigmatism (SIA) was calculated according to the Alpíns method^[16-17].

Statistical Analysis All the data were analyzed by using the SPSS 20.0 software (SPSS Inc. Chicago, IL, USA). Measurement data was presented with mean±SD and student *t*-test was employed for the comparison between 2 groups. Counted data were presented with percentage and the comparison between 2 groups was calculated using χ^2 test. $P < 0.05$ was considered as statistically significant.

RESULTS

Patient Data As shown in Table 1, group A was comprised of 31 patients (31 eyes, 26 males and 5 females) with the mean age of $53.93 \pm 17.08y$ (range: 13-78y) who underwent sutured IF-IOL implantation. Fifteen eyes in 15 patients had ocular trauma, 10 eyes had left aphakia after cataract extraction, 4 eyes were processed with anterior vitrectomy, and 2 eyes were IOL dislocation. Group B was comprised of 31 patients (32 eyes, 24 males and 7 females) with an age range of $53.13 \pm 15.92y$ (range: 15-75y) who underwent SF-IOL implantation. In group B, 17 eyes in 17 patients had ocular trauma, 4 eyes had left aphakia after cataract extraction, 8 eyes had undergone anterior vitrectomy, and 3 eyes in 2 patients had IOL dislocation. No significant difference of age, gender, ocular trauma, left aphakia after cataract extraction, anterior vitrectomy, IOL dislocation and preoperative BCVA was found between the two groups.

Postoperative Uncorrected Visual Acuity and Preoperative Best Corrected Visual Acuity Between Two Groups

In group A, 38.71% (12/31) of eyes had a higher postoperative UCVA value than preoperative BCVA value, 32.26% (10/31) had the same postoperative UCVA value with the preoperative BCVA value, and 29.03% (9/31) had a lower postoperative UCVA value than the preoperative BCVA value. In group B, 12.50% (4/32) of eyes had a higher postoperative UCVA value than the preoperative BCVA value, 31.25% (10/32) had the same postoperative UCVA value with the preoperative BCVA value, and 56.25% (18/32) had a lower postoperative BCVA value than the preoperative BCVA value (Table 2).

Table 1 Pre-operative data of the patients

Characteristics	Group A	Group B	$\bar{x} \pm s$ <i>P</i>
Age (a)	53.93±17.08	53.13±15.92	0.794
Gender			1.00
M	26	24	
F	5	7	
Preoperative pathology			
Ocular trauma	15	17	NS
Left aphakia after cataract extraction	10	4	0.068
Anterior vitrectomy	4	8	0.199
IOL dislocation	2 ^a	3 ^b	NS
Pre-BCVA	0.44±0.18	0.43±0.19	0.881

IOL: Intraocular lens; Pre-BCVA: Preoperative best corrected visual acuity; NS: Not significant; Group A: Iris-fixated foldable lens implantation group; Group B: Scleral-fixated foldable lens implantation group. ^aPreoperative refraction, 10.50 D±1.14 D (range 8.5 D-13 D); ^bPreoperative refraction, 10.53 D±1.19 D (range 8.5 D-13 D).

Table 2 The postoperative UCVA and preoperative BCVA between 2 groups

Outcome	Group A	Group B	χ^2	<i>P</i>
Post-UCVA>pre-BCVA	38.71% (12/31)	12.50% (4/32)	5.709	0.017
Post-UCVA=pre-BCVA	32.26% (10/31)	31.25% (10/32)	0.932	0.007
Post-UCVA<pre-BCVA	29.03% (9/31)	56.25% (18/32)	4.763	0.029

Post-UCVA: Postoperative uncorrected visual acuity; Pre-BCVA: Preoperative best corrected visual acuity. Group A: Iris-fixated foldable lens implantation group; Group B: Scleral-fixated foldable lens implantation group.

The percentage of eyes with lower postoperative UCVA than preoperative BCVA was significantly lower in group A than that in group B (29.03% vs 56.25%; $\chi^2=4.763$, $P=0.029$). In addition, the percentage of patients who had a higher postoperative UCVA than preoperative BCVA was significantly higher in group A (38.71% vs 12.50%; $\chi^2=5.709$, $P=0.017$) than that in group B.

Refraction and Corneal Astigmatism in Two Groups As shown in Table 3, the post-UCVA in group A was higher than that in group B (0.43±0.19 vs 0.35±0.18, $P=0.043$). In addition, spherical equivalent (SE) in group A showed a trend towards myopia [-0.47 D±0.58 D (range, -2.25 D to -0.75 D)] while in group B showed a hyperopic trend [0.50 D±0.43 D (range, -0.5 D to -1.75 D)]. The difference between two groups was statistically significant ($P<0.001$). There was a significant difference of retinoscopic cylinder magnitude between group A [0.84±0.53 D (range: -2 D to 0 D)] and group B [1.23 D±0.70 D (range: -3 D to +2.5 D), $P=0.019$]. However, no significant difference of postoperative BCVA and corneal astigmatic was found between the two groups ($P>0.05$).

Complications The intraoperative and postoperative complications are shown in Table 4. More cases were found on lens tilt or posterior offset and suture knot exposure in group B than group A, while similar number of intraoperative hyphema, vitreous hemorrhage and secondary glaucoma were found between 2 groups.

DISCUSSION

In the present study, we prospectively analyzed 62 patients (63 eyes) who underwent modified IF-IOL or SF-IOL implantation and evaluated the differences between these

Table 3 Comparison of postoperative visual acuities, refraction and corneal astigmatism between group A and group B

Outcome	Group A	Group B	<i>P</i>	<i>t</i>
Post-UCVA	0.43±0.19	0.35±0.18	0.043 ^a	2.25
Post-BCVA	0.55±0.22	0.53±0.19	0.249	0.94
SE (D)	-0.47±0.58	0.50±0.43	0.000 ^a	-7.47
Cylinder (D)	0.84±0.53	1.23±0.70	0.019 ^a	-2.40
Corneal astigmatic				
Pre-A (D)	0.76±0.49	0.74±0.48	0.76	0.22
Post-A (D)	0.80±0.51	0.79±0.43	0.51	0.06
SIA (D)	0.39±0.14	0.40±0.16	0.37	0.19

UCVA: Uncorrected visual acuity; BCVA: Best corrected visual acuity; SE: Spherical equivalent; Pre-A: Preoperative astigmatism; Post-A: Postoperative astigmatism; SIA: Surgically induced astigmatism; Group A: Iris-fixated foldable lens implantation group; Group B: Scleral-fixated foldable lens implantation group. ^aStatistically significant difference.

Table 4 Intraoperative and postoperative complications in groups A and B

Complications (n)	Group A	Group B
Intraoperative hyphema	4	5
Vitreous hemorrhage	2	2
Lens tilt or posterior offset	0	6
Secondary glaucoma	1	1
Suture knot exposure	0	4
Total	7	18

Group A: Iris-fixated foldable lens implantation group; Group B: Scleral-fixated foldable lens implantation group.

two types of implantation methods. We found that the modified sutured IF-IOL implantation was a safe and efficient treatment in patients with insufficient capsular support after cataract extraction. Also, this study is the first time to show the safety and efficacy of sutured IF-IOL in Chinese population.

Zeh *et al* [18] reported 121 consecutive cases of secondary IOL implantation or IOL exchange in a retrospective review. They found that VA was 20/80 or better in 58.3% and 20/40 or better in 30.5% of eyes with transplants. Without transplants, VA was 20/80 or better in 82.0% and 20/40 or better in 57.1%. In a clinical study investigating IF-IOL for the correction of myopia in 41 eyes, Tehrani *et al* [19] reported a significant improvement of UCVA with 82% of eyes reaching 20/25 or better. In addition, after comparison of IF-IOL and SF-IOL in Marfan syndrome with lens subluxation, Zheng *et al* [20] found that there was no statistically significant difference of BCVAs between IF-IOL and SF-IOL group, which was consistent with our study. However, they did not analyze postoperative UCVA between these two groups. In this study, the postoperative UCVA in IF-IOL group was higher than that in SF-IOL group (0.43±0.19 vs 0.35±0.18, $P=0.043$). These findings may illustrate that IF-IOL can result in a lower risk of post-operative astigmatism than SF-IOL group. According to previous studies, sutured IF-IOLs could present a relative fixated position near the nodal point of the eyes while SF-IOLs have

a more flexible anterior or posterior position which depends on the position of SF haptics [21-22]. In our procedure, we attempted to position all SF haptics 1.5 mm posterior to the limbus. However, due to anatomic differences among patients and discrepancy on operation processing, the accurate implantation of IOL into above location could not be fulfilled each time and would result in the variable of IOL location on optic. Despite similar SE refraction was found in 2 groups, the post-operative retinoscopy sphere showed an overall myopic endpoint (SE was $-0.47 \text{ D} \pm 0.58 \text{ D}$ and sphere range was -2 D to 0 D) in the sutured IF-IOL group while an overall hyperopic endpoint with a larger range on the sphere endpoint (SE was $0.50 \text{ D} \pm 0.43 \text{ D}$ and sphere range was -3 D to 2.5 D) in the sclera-fixated group, which was significantly larger than 0.5 D . Condon *et al* [23] described 46 patients who underwent iris fixation of a foldable acrylic IOL, which was similar to our study.

IOL tilt and decentration often occur during scleral fixation because the IOL position usually depends on 2 fixated points which are sometimes not on the same plane. Conversely, both of them tend to be less significant during iris fixation because the 2 fixated points do lie on the same plane and no significant deformity was found in the iris. There is evidence that IOL tilt and decentration could cause lens-induced astigmatism [24-25], which was in consistent with our result, that retinoscopic astigmatism was higher in SF-IOL group than in IF-IOL group. And no significant difference was found in corneal astigmatism between the two groups. Moreover, obvious IOL tilt and decentration were found in some eyes in SF-IOL group which was not seen on post-operative examination in IF-IOL group.

With regard to the complications, we observed a similar number of intraoperative hemorrhage in IF-IOL and SF-IOL group. The occurrence of intraoperative hemorrhage in SF-IOL implantation may be explained by higher possibilities of hemorrhage in the posterior of the eyes. In SF-IOL group, more persistent vitreous hemorrhage and concomitant longer visual recovery with anterior chamber hyphema were presented. In our study, no IOL tilt, decentration or suture knot exposure was seen in the IF-IOL group, which was also consistent with a previous study reported by Ganekal *et al* [26].

Based on the findings in our study, we concluded that the sutured IF-IOL technique resulted in better visual outcomes and was associated with a higher level of safety than the SF-IOL technique. The superior visual outcome was related with a higher predictability on refractive outcome and a lower level of induced astigmatism in the IF-IOL technique compared with the SF-IOL technique. However, this technique also has some certain disadvantages: 1) a relative intact iris structure was needed preoperatively, therefore this technique cannot be applied in cases of severe iris trauma,

iridodialysis, or atrophy. From our experience, the iris suture fixated technique described here can be performed when the iris impairment is not more than one quadrant. 2) The surgery is conservative in mydriatic pupils because it is more challenging to achieve a good IOL centration. 3) This technique is also associated with some other risks, such as impacts on iris tissue, pupil dilation restriction, pupil ovalization, cystoid macular edema, and secondary glaucoma.

There are still some limitations in our study. First, the degree of postoperative tilt of the IOLs in each group was not measured, and the correlation between the degree of the tilt and the retinoscopic astigmatism was not analyzed. Second, follow-up for complications was short and lack of data about other important parameters like coefficient of variation and percentage of hexagonal cells. Therefore, long-term follow-up data of complications are needed to confirm the results. In addition, since the case number showed here is small, further studies with more cases are needed to perform in future.

In conclusion, sutured IF-IOL implantation provides a safe and effective advantage in refraction to treat the patients with insufficient capsular support after cataract extraction in China. Compared with SF-IOL implantation, IF-IOL implantation can result in superior visual improvement and fewer complications.

ACKNOWLEDGEMENTS

Foundation: Supported by Research Fund of Shandong Public Health Department (No.2009HZ038).

Conflicts of Interest: Zhang H, None; Zhao J, None; Zhang LJ, None; Liu J, None; Liu Y, None; Song W, None; Tian QF, None; Wang Q, None; Hamilton DR, None.

REFERENCES

- 1 Kamiya K, Igarashi A, Shimizu K, Matsumura K, Komatsu M. Visual performance after posterior chamber phakic intraocular lens implantation and wavefront-guided laser in situ keratomileusis for low to moderate myopia. *Am J Ophthalmol* 2012;153(6):1178-1186.
- 2 Chang DF, Masket S, Miller KM, Braga-Mele R, Little BC, Mamalis N, Oetting TA, Packer M; ASCRS Cataract Clinical Committee. Complications of sulcus placement of single-piece acrylic intraocular lenses: recommendations for backup IOL implantation following posterior capsule rupture. *J Cataract Refract Surg* 2009;35(8):1445-1458.
- 3 Al-Swailem SA, Al-Rajhi AA. Decentration and cataract formation 10 years following posterior chamber silicone phakic intraocular lens implantation. *J Refract Surg* 2006;22(5):513-515.
- 4 Kodjikian L, Beby F, Spire M, Gambrelle J, Hubert I, Burillon C, Grange JD, Garweg JG. Combined pars plana phacofragmentation, vitrectomy, and Artisan lens implantation for traumatic subluxated cataracts. *Retina* 2006; 26(8):909-916.
- 5 van der Meulen IJ, Gunning FP, Vermeulen MG, de Smet MD. Artisan lens implantation to correct aphakia after vitrectomy for retained nuclear lens fragments. *J Cataract Refract Surg* 2004;30(12):2585-2589.

- 6 Acar N, Kapran Z, Altan T, Kucuksumer Y, Unver YB, Polat E. Secondary iris claw intraocular lens implantation for the correction of aphakia after pars plana vitrectomy. *Retina* 2010;30(1):131-139.
- 7 Asadi R, Kheirkhah A. Long-term results of scleral fixation of posterior chamber intraocular lenses in children. *Ophthalmology* 2008;115 (1): 67-72.
- 8 Kwong YY, Yuen HK, Lam RF, Lee VY, Rao SK, Lam DS. Comparison of outcomes of primary scleral-fixated versus primary anterior chamber intraocular lens implantation in complicated cataract surgeries. *Ophthalmology* 2007;114(1):80-85.
- 9 Guell JL, Velasco F, Malecaze F, Vazquez M, Gris O, Manero F. Secondary Artisan-Versysise aphakic lens implantation. *J Cataract Refract Surg* 2005;31(12):2266-2271.
- 10 Lovisolo CF, Reinstein DZ. Phakic intraocular lenses. *Surv Ophthalmol* 2005;50(6):549-587.
- 11 Alio JL, Galal A, Mulet ME. Surgical correction of high degrees of astigmatism with a phakic toric-iris claw intraocular lens. *Int Ophthalmol Clin* 2003;43(3):171-181.
- 12 McCannel MA. A retrievable suture idea for anterior uveal problems. *Ophthalmic Surg* 1976;7(2):98-103.
- 13 Kopel AC, Carvounis PE, Hamill MB, Weikert MP, Holz ER. Iris-sutured intraocular lenses for ectopia lentis in children. *J Cataract Refract Surg* 2008;34(4):596-600.
- 14 Zandian M, Moghimi S, Fallah M, Crandall A. Ab externo iris fixation of posterior chamber intraocular lens through small incision. *J Cataract Refract Surg* 2010;36(12):2032-2034.
- 15 Rao R, Sasidharan A. Iris claw intraocular lens: a viable option in monocular surgical aphakia. *Indian J Ophthalmol* 2013;61(2):74-75.
- 16 Alpina NA. A new method of analyzing vectors for changes in astigmatism. *J Cataract Refract Surg* 1993;19(4):524-533.
- 17 Kawahara A, Kurosaka D, Yoshida A. Comparison of surgically induced astigmatism between one-handed and two-handed cataract surgery techniques. *Clin Ophthalmol* 2013;7:1967-1972.
- 18 Zeh WG, Price FW Jr. Iris fixation of posterior chamber intraocular lenses. *J Cataract Refract Surg* 2000;26(7):1028-1034.
- 19 Tehrani M, Dick HB. Short-term follow-up after implantation of a foldable iris-fixated intraocular lens in phakic eyes. *Ophthalmology* 2005; 112(12):2189-2195.
- 20 Zheng D, Wan P, Liang J, Song T, Liu Y. Comparison of clinical outcomes between iris-fixated anterior chamber intraocular lenses and scleral-fixated posterior chamber intraocular lenses in Marfan syndrome with lens subluxation. *Clin Experiment Ophthalmol* 2012;40(3):268-274.
- 21 Yen KG, Reddy AK, Weikert MP, Song Y, Hamill MB. Iris-fixated posterior chamber intraocular lenses in children. *Am J Ophthalmol* 2009; 147(1):121-126.
- 22 Zhang Y, Sun D, Zhang Z, Xiao H, Peng S. Combined silicone oil removal with secondary implantation of anterior chamber or sclera-fixed posterior chamber intraocular lenses. *Eur J Ophthalmol* 2013;23 (5): 697-704.
- 23 Condon GP, Masket S, Kranemann C, Crandall AS, Ahmed II. Small-incision iris fixation of foldable intraocular lenses in the absence of capsule support. *Ophthalmology* 2007;114(7):1311-1318.
- 24 Koch DD, Jenkins RB, Weikert MP, Yeu E, Wang L. Correcting astigmatism with toric intraocular lenses: effect of posterior corneal astigmatism. *J Cataract Refract Surg* 2013;39(12):1803-1809.
- 25 Mojzis P, Piñero DP, Civrteckova V, Rydlova I. Analysis of internal astigmatism and higher order aberrations in eyes implanted with a new diffractive multifocal toric intraocular lens. *Graefes Arch Clin Exp Ophthalmol* 2013;251(1):341-348.
- 26 Ganekal S, Venkataratnam S, Dorairaj S, Jhanji V. Comparative evaluation of suture-assisted and fibrin glue--assisted scleral fixated intraocular lens implantation. *J Refract Surg* 2012;28(4):249-252.